



IMPORTANCE OF THE CORRECT ASSOCIATION OF CLINICAL, IMAGINOLOGICAL AND HISTOPATHOLOGICAL EXAMS IN THE DIAGNOSIS OF OSTEOSARCOMA

IMPORTÂNCIA DA CORRETA ASSOCIAÇÃO DE EXAMES CLÍNICOS, IMAGINOLÓGICOS E HISTOPATOLÓGICOS NO DIAGNÓSTICO DE OSTEOSSARCOMA

IMPORTANCIA DE LA CORRECTA ASOCIACIÓN DE EXÁMENES CLÍNICOS, DE IMAGEN E HISTOPATOLÓGICOS EN EL DIAGNÓSTICO DEL OSTEOSARCOMA

Diego Leonardo de Souza¹, Victor Milis Wandelli², Cleomar Donizeth Rodrigues³, Elimar Fernando Bauer⁴, Luiz Carlos de Lima Dias Júnior⁵, Fabiane Kellem Oliveira dos Santos Cesário⁶, Virgílio Pimentel Galvão⁷

e422702

<https://doi.org/10.47820/recima21.v4i2.2702>

RECEIVED: 01/01/2023

APPROVED: 02/01/2023

PUBLICADO: 02/09/2023

ABSTRACT

Justification: Osteosarcoma, a malignant neoplasm characterized by the production of osteoid tissue and immature bone that proliferates through the cell stroma, is a rare disease of high aggressiveness associated with severe morbidity and mortality. Regarding the craniofacial region, osteosarcomas account for less than 1% of all malignant neoplasms, with the mandible being the main bone affected. In the diagnostic process, there is a similarity with benign lesions, which requires a detailed clinical analysis and complementary exams for the definitive diagnosis. Treatment is based on radical surgical removal of the lesion with safety margins, with or without radiotherapy and/or chemotherapy. Osteosarcomas of the head and neck normally affect individuals between the third and fourth decade of life, with a higher prevalence in females. This work aims to clarify the methods used for the diagnosis, treatment and follow-up of patients with osteosarcoma in the mandible. Case report: A 35-year-old female patient came to the Center for Stomatology and Patients with Systemic Changes (CEPAS) complaining of intermittent pain, tooth mobility with purulent secretion and facial asymmetry. The diagnostic process consisted of clinical, radiographic, tomographic and histopathological examinations, in a transdisciplinary approach. As treatment, partial mandibulectomy, chemotherapy and radiotherapy were performed. Conclusions: This study envisages the discussion of the complexity of diagnosis and prognosis of patients with osteosarcoma, as well as the need for humanized action by health teams, to provide patient care without focusing only on the disease.

KEYWORDS: Diagnosis. Osteosarcoma. Radiology. Panoramic radiography. Tomography.

RESUMO

Justificativa: O osteossarcoma, neoplasia maligna caracterizada pela produção de tecido osteóide e osso imaturo que se prolifera através do estroma celular, é uma doença rara de alta agressividade associada a quadros severos de morbidade e mortalidade. Em relação à região craniofacial, os osteossarcomas pertencem a menos de 1% de todas as neoplasias malignas, sendo a mandíbula o principal osso afetado. No processo diagnóstico há semelhança com lesões benignas, o que exige análise clínica detalhada e exames complementares para o diagnóstico definitivo. O tratamento baseia-se na remoção cirúrgica radical da lesão com margens de segurança, associada ou não à radioterapia e/ou quimioterapia. Os osteossarcomas de cabeça e pescoço afetam normalmente

¹ Instituto Orofacial das Américas.

² Universidade Federal de Santa Catarina.

³ Centro universitário do Planalto Central Aparecido dos Santos.

⁴ Instituto Orofacial das Américas.

⁵ Universidade Federal de Santa Catarina.

⁶ Oncologista Clínica do Grupo Acreditar e DFSTAR/Oncologia D'Or, Referência Técnica em Oncologia Clínica da Secretaria de Saúde do Distrito Federal e doutora em Ciências Genômicas e Biotecnologia. Mestre em Ciências Genômicas e Biotecnologia pela Universidade Católica de Brasília. Membro efetivo da ASCO - American Society of Clinical Oncology e da SBOC - Sociedade Brasileira de Oncologia Clínica.

⁷ Faculdade de Odontologia da USP - FOUASP.



RECIMA21 - REVISTA CIENTÍFICA MULTIDISCIPLINAR ISSN 2675-6218

IMPORTANCE OF THE CORRECT ASSOCIATION OF CLINICAL, IMAGINOLOGICAL AND HISTOPATHOLOGICAL EXAMS IN THE DIAGNOSIS OF OSTEOSARCOMA

Diego Leonardo de Souza, Victor Milis Wandelli, Cleomar Donizeth Rodrigues, Elimar Fernando Bauer, Luiz Carlos de Lima Dias Júnior, Fabiane Kellem Oliveira dos Santos Cesário, Virgílio Pimentel Galvão

indivíduos entre a terceira e quarta década de vida, com maior prevalência para o gênero feminino. Este trabalho tem como objetivo esclarecer os métodos empregados para o diagnóstico, tratamento e acompanhamento de paciente com osteossarcoma em mandíbula. Relato de caso: Paciente do gênero feminino, 35 anos, compareceu ao Centro de Estomatologia e de Pacientes com Alterações Sistêmicas (CEPAS) queixando-se de dor intermitente, mobilidade dentária com secreção purulenta e assimetria facial. O processo do diagnóstico consistiu em exames clínico, radiográfico, tomográfico e histopatológico, numa abordagem transdisciplinar. Como tratamento foi realizada a mandibulectomia parcial, quimioterapia e radioterapia. Conclusões: Este estudo vislumbra a discussão da complexidade do diagnóstico e prognóstico de pacientes com osteossarcoma, assim como a necessidade da atuação humanizada das equipes de saúde, para proporcionar uma assistência ao paciente sem focar apenas na doença.

PALAVRAS CHAVES: Diagnóstico. Osteossarcoma. Radiologia. Radiografia Panorâmica. Tomografia

RESUMEN

Justificativa: O osteossarcoma, neoplasia maligna caracterizada pela produção de tecido osteóide e osso imaturo que se prolifera a través del estroma celular, é uma doença rara de alta agressividade associada a quadros severas de morbidade e mortalidade. Em relação à região craniofacial, os osteossarcomas pertencem a less of 1% of all as neoplasias malignas, sendo a mandíbula or principal osso afetado. Ningún proceso de diagnóstico tiene lesiones benignas, o requiere un análisis clínico detallado y exámenes complementarios para el diagnóstico definitivo. O tratamento baseia-se na remoção cirúrgica radical da lesão com márgenes de segurança, associada ou não à radioterapia e/ou quimioterapia. Os osteossarcomas de cabeça e pescoço afetam normalmente indivíduos entre a terceira e quarta década de vida, com maior prevalência para o gênero feminino. Este tratamiento tiene como objetivo esclarecer los métodos empleados para el diagnóstico, el tratamiento y el acompañamiento del paciente con osteosarcoma en la mandíbula. Relato de caso: Paciente de género femenino, 35 años, compareceu ao Centro de Estomatologia e de Pacientes com Alterações Sistêmicas (CEPAS) queixando-se de dor intermitente, mobilidade dentária com secreção purulenta and assimetria facial. El proceso de diagnóstico consiste en exámenes clínicos, radiográficos, tomográficos e histopatológicos, numa abordagem transdisciplinar. Como tratamento para realizar una mandibulectomia parcial, quimioterapia y radioterapia. Conclusiones: Este estudio visual se analizó sobre la complejidad del diagnóstico y el pronóstico de los pacientes con osteosarcoma, así como la necesidad de la actualización humanizada de los equipos de salud, para proporcionar una asistencia al paciente que se enfoca apenas en la dolencia.

PALABRAS CLAVE: Diagnóstico. Osteosarcoma. Radiología. Radiografía Panorámica. Tomografía

INTRODUCTION

Osteogenic sarcoma or osteosarcoma (OS) is a rare and highly aggressive disease of the jaws associated with severe morbidity and mortality in most cases (1,2). This malignant neoplasm is characterized by the production of osteoid tissue and immature bone. These growths proliferate through the cell stroma, promote bone changes in the oral mucosa and can also affect teeth and adjacent structures (1,3).

The affected population ranges widely in age but occurrence peaks in the fourth decade of life. In the head and neck region, OS is associated with both the mandible and maxilla and represent 1% of malignant lesions of these bones (4). Some studies showed predominance in the mandibular region (5) and others in the maxilla (6). Clinically, OS causes an increase in volume, accompanied by



RECIMA21 - REVISTA CIENTÍFICA MULTIDISCIPLINAR ISSN 2675-6218

IMPORTANCE OF THE CORRECT ASSOCIATION OF CLINICAL, IMAGINOLOGICAL AND HISTOPATHOLOGICAL EXAMS IN THE DIAGNOSIS OF OSTEOSARCOMA

Diego Leonardo de Souza, Victor Milis Wandelli, Cleomar Donizeth Rodrigues, Elimar Fernando Bauer, Luiz Carlos de Lima Dias Júnior, Fabiane Kellem Oliveira dos Santos Cesário, Virgílio Pimentel Galvão

edema, facial deformity and trismus, mobility or loss of teeth, pain, paresthesia or anesthesia of the affected area, nasal obstruction and epistaxis (7).

Three histological types related to the type of extracellular matrix produced by the tumor cells are described as osteoblastic, chondroblastic and fibroblastic, with chondroblastic being the most frequently found (8). They are characterized by the production of osteoid tissue and immature bone which propagate through the cell stroma and occasionally chondroid material and fibrous connective tissue. The cells may also present a very compact unilocular mass, formed essentially of bone matrix, surrounded by neoplastic osteoblasts that produced it (7,8).

Radiographically, OS is observed as radiopaque and radiolucent or mixed areas and thickening of the lateral periodontal ligament. The cortical bone presents exophytic projections similar to “sunbeams” (5). Although they are low-cost and easy-to-perform tests, the overlapping of anatomical structures on radiographs sometimes makes it difficult to establish diagnostic hypotheses (4). Computed tomography (CT) presents high image quality and is excellent for detecting morphological changes resulting from benign or malignant diseases in the oral cavity (9,10). In it, OS are visualized as compact and central, unilocular radiopaque masses with, in most cases, aggressive destruction of cortical bone and involvement of adjacent soft tissues (11).

The association of these imaging exams with the biopsy, followed by the histopathological exam, is the gold standard for the diagnosis of OS and the vast majority of oral lesions (12). Due to the fact that OS resembles chondrosarcoma and other neoplasms, other tests may be necessary to confirm the diagnosis by means of CT, whether accompanied or not by histopathology (9).

The immunohistochemical expression of p53, MDM2, PCNA and KI67 proteins helps to establish the diagnosis of OS. Immunohistochemical analysis of 25 OS from the head and neck showed prevalent positivity in 52% of cases for p53, 24% for MDM2, 84% for CDK4, 92% for PCNA, and 88% for KI67 (13).

The most appropriate treatment for OS is surgical resection of the lesion with a wide margin of safety. The use of radiotherapy and/or chemotherapy promotes a long-term survival of approximately 45%, and may be recommended after radical surgery (5,6,13,14).

Chindia et al. (1998) (6) followed 14 cases of OS, with 11 in the maxilla, 2 in the mandible and 1 in the zygomatic arch, with an equal distribution between the sexes and with a mean age of 29.7 years. Pain and rapid swelling were the most common clinical features while radiographic and histological features were highly variable. Six of the patients who were followed for periods of 2 to 6 months had extensive recurrences and died. The treatments used were chemotherapy, radiotherapy and surgery, alone or in combination.

In another study, the most common location was the mandible (60%) with the predominant histological type being chondroblastic (72%). Most were treated by surgery alone or in combination with chemotherapy. The 5-year and 10-year survival rates were 59% and 49%, respectively (13).



RECIMA21 - REVISTA CIENTÍFICA MULTIDISCIPLINAR ISSN 2675-6218

IMPORTANCE OF THE CORRECT ASSOCIATION OF CLINICAL, IMAGINOLOGICAL AND HISTOPATHOLOGICAL EXAMS IN THE DIAGNOSIS OF OSTEOSARCOMA

Diego Leonardo de Souza, Victor Milis Wandelli, Cleomar Donizeth Rodrigues, Elimar Fernando Bauer, Luiz Carlos de Lima Dias Júnior, Fabiane Kellem Oliveira dos Santos Cesário, Virgílio Pimentel Galvão

A study that presented 14 cases of OS in patients with a mean age of 33 years, found 6 OS (42%) in the mandible and 8 (58%) in the maxilla. The histological types found were chondroblastic, osteoblastic, fibroblastic and a type similar to malignant fibrous histiocytoma. All underwent surgical resection, pre and postoperative chemotherapy and postoperative radiotherapy (14).

Another study evaluated 25 patients with a mean age of 36.9 years, with a slight predominance of females, and showed that the most common clinical aspects were swelling, pain, ulceration and neurological disorder. Radiographically, they presented radiopaque and radiolucent areas. Histologically, they showed immature bone trabeculae, separated by a stroma that varied from mild to high cytological grade. Some regions were marked by high atypia and mitotic activity while many areas were marked with chondroid and osteoid neoplastic formation. Local recurrence was frequent and metastases were rare and late (15).

A published clinical case of a 20-year-old female patient presented a slight increase in volume in the lower premolar region, of hard consistency, painless on palpation and without other manifestations. The periapical radiograph showed a radiographic image suggestive of root resorption and diffuse bone rarefaction in the periapical of 34, followed by endodontic treatment of the tooth with necrotic pulp. After 11 days there was a rapid evolution, with visible facial asymmetry, associated with numbness on the left side of the lower lip. The vestibular region was swollen, red and bleeding. Among the blood and radiographic tests performed, the occlusal radiography stood out; the image was compatible with an area of bone destruction and abnormal formation in the region, with a ground-glass appearance, masking details in the bone trabeculae. The external cortex showed great radiopacity similar to "sunshine", suggesting the diagnosis of OS (16).

This article aims to present the clinical case of an OS in the mandible, emphasizing the importance of constant monitoring of the patient and the correct association of clinical, imaging and histopathological aspects to establish its diagnosis. In viewing the radiographic and histopathological similarities with other pathologies, diagnostic errors may be avoided that would otherwise delay the beginning of the treatment and decrease the cure and survival rates of the patient.

CLINICAL CASE

A 35-year-old female patient, a former smoker who maintained the habit for 15 years, sought consultation at the Center for Stomatology and Patients with Systemic Changes (CEPAS). She presented with a main complaint of facial swelling with rapid volume progression, initially noticed 6 months prior, and spontaneous and intermittent pain on the left side of the face. She presented radiographic and tomographic exams of the lesion, as well as a biopsy report, requested by a professional consulted before turning to CEPAS. The previous histopathological result was deemed a leiomyoma of the oral mucosa, characterized by the absence of malignancy. After experiencing no improvement, she sought a new evaluation.



RECIMA21 - REVISTA CIENTÍFICA MULTIDISCIPLINAR ISSN 2675-6218

IMPORTANCE OF THE CORRECT ASSOCIATION OF CLINICAL, IMAGINOLOGICAL AND HISTOPATHOLOGICAL EXAMS IN THE DIAGNOSIS OF OSTEOSARCOMA

Diego Leonardo de Souza, Victor Milis Wandelli, Cleomar Donizeth Rodrigues, Elimar Fernando Bauer, Luiz Carlos de Lima Dias Júnior, Fabiane Kellem Oliveira dos Santos Cesário, Virgílio Pimentel Galvão

The intraoral clinical examination revealed an exophytic, sessile lesion, rigid on palpation, similar in color to the adjacent mucosa, with purulent exudate, involving the area of teeth 33 and 35, which had grade II mobility (FIG. 1).

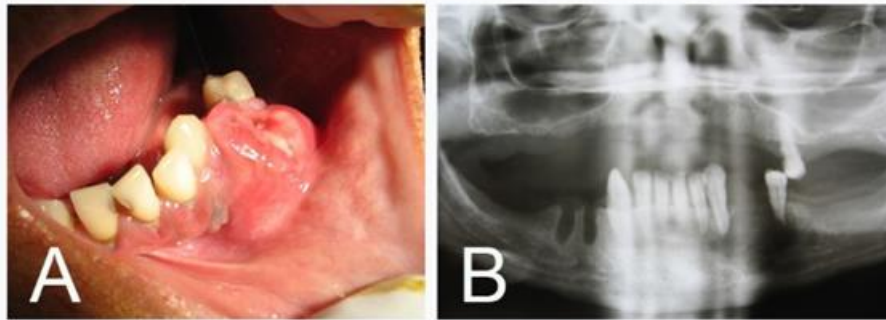


Figure 1. A. Intraoral aspect of the lesion associated with teeth 33 and 35. B. Panoramic radiograph with a radiolucent lesion, with irregular contour, on the left side of the mandible and external root resorption on teeth 33 and 35.

Extraoral examination revealed facial asymmetry, with swelling on the left side of the mandible, extending to the region of the mental protuberance and absence of lymphadenopathy in the head and neck. When evaluating the panoramic radiograph, a radiolucent lesion with irregular margins on the left side was noticed, involving the mental region and the body of the mandible. Along with this was the destruction of the alveolar bone, involvement of the mental foramen and external root resorption in teeth 33 and 35 (FIG. 1). A CT with contrast was requested, which showed a lesion with lytic and aggressive characteristics, measuring approximately 5.2 cm in its greatest diameter. The external cortex of the mandible was destroyed, with the lesion extending to the soft tissues and formation of osteoid tissue, giving the lesion the classic “sunbeams” appearance. The mandibular canal was also compromised (FIG. 2).

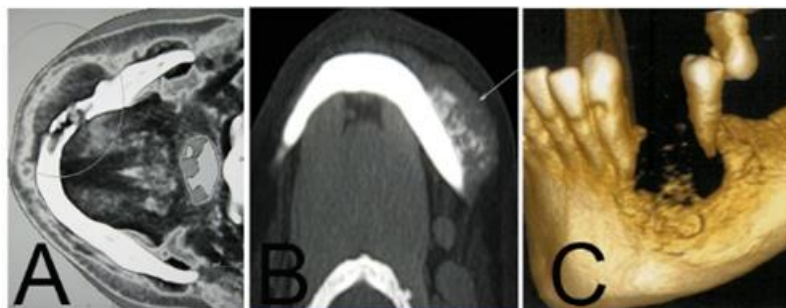


Figure 2 – Contrast-enhanced jaw CT. A. Axial reconstruction, in which the mandibular bone structure and adjacent soft tissues are compromised. B. Axial reconstruction with a lesion on the left side, with a “sunshine” appearance by the formed osteoid tissue. C. 3D reconstruction, in buccal view from the left side, with bone destruction involving teeth 33 and 35.



RECIMA21 - REVISTA CIENTÍFICA MULTIDISCIPLINAR ISSN 2675-6218

IMPORTANCE OF THE CORRECT ASSOCIATION OF CLINICAL, IMAGINOLOGICAL AND HISTOPATHOLOGICAL EXAMS IN THE DIAGNOSIS OF OSTEOSARCOMA

Diego Leonardo de Souza, Victor Milis Wandelli, Cleomar Donizeth Rodrigues, Elimar Fernando Bauer, Luiz Carlos de Lima Dias Júnior, Fabiane Kellem Oliveira dos Santos Cesário, Virgílio Pimentel Galvão

One week after the initial consultation, a new incisional biopsy was performed in the affected area. The fragment was fixed in 10% formalin and sent for histopathological analysis at the pathology laboratory of the Hospital de Base do Distrito Federal (HBDF). The result of this second examination showed fibromatosis, with no characteristics of malignancy. The patient continued to be monitored by the CEPAS team, who noticed that the lesion had progressed quickly and with clinical behavior incompatible with the diagnosis of the histopathological examination. In view of this, it was decided to perform another biopsy, but this time including part of the bone tissue. Again, the surgical specimen was preserved in formalin and sent to the HBDF. The result was OS, predominantly osteoblastic, with the presence of a nonspecific chronic inflammatory process in the mucosa and focal neoplastic infiltration (FIG 3).

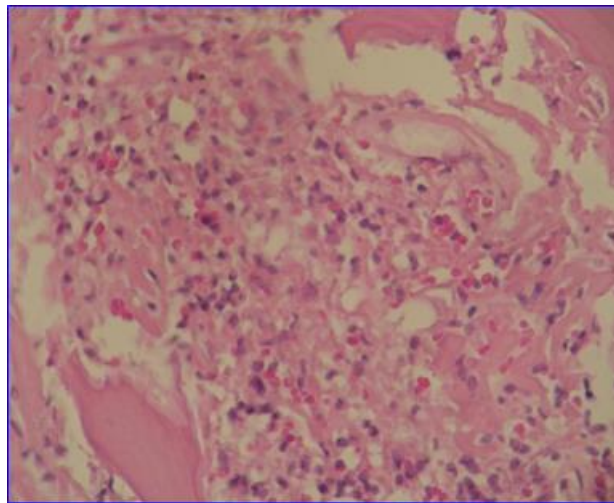


Figure 3. Histological section of the lesion, showing high-grade osteosarcoma, predominantly osteoblastic.

With the diagnosis of malignant lesion, the patient was referred to the Head and Neck Surgery Sector of the HBDF, where a radical surgical resection of the lesion was performed with a safety margin of 1 cm. The removed piece included part of the mandible associated with the left sublingual salivary gland. This was sent for histopathological examination, which found no compromised lymph nodes or vascular and neural invasion of the lesion. After 3 months of follow-up, there was no evidence of recurrence. However, in the seventh month of follow-up, the patient reported the onset of discomfort in the region close to the ear and swelling on the left side of the face. A new CT was requested, and the analysis of the images associated with the clinical evaluation allowed us to conclude that the lesion had recurred (FIG 4).

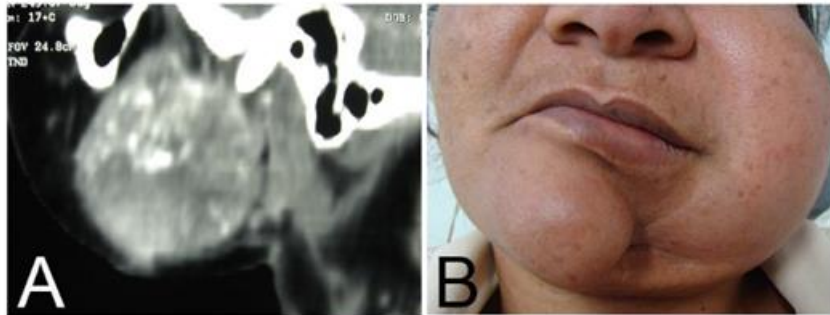


Figure 4. A. Sagittal contrast-enhanced CT reconstruction, showing signs of lesion recurrence with a characteristic “sunshine” appearance, due to the production of osteoid tissue. B. Extraoral view with marked asymmetry on the left side, seven months after surgery.

The symptomatology was due to the progression of the lesion to the region of the ascending ramus of the mandible. There was a rapid evolution of the clinical picture, and the patient was again referred by the CEPAS team to the Head and Neck Surgery Sector of the HBDF to assess the possibility of performing another surgical procedure. Surgery was performed, including part of the maxilla due to its involvement by the lesion, followed by radiotherapy and chemotherapy.

Post-surgical histopathological examination detected the presence of compromised margins, which unfortunately indicated an unfavorable prognosis for the patient. Preservation of the case was carried out, giving hygiene and care guidelines for the region involved. The patient died after 6 months.

DISCUSSION

OS is a rare malignant lesion of mesenchymal origin which can produce osteoid tissue and immature bone and mainly affects the long bones (1,3). In the head and neck region, it is associated with the mandible and maxilla and represents 1% of all malignancies in this region (4). It affects a wide age range, with a peak occurring in the fourth decade of life, and studies have shown predominance in the mandibular region (7).

Accurate diagnosis is essential for the ideal treatment protocol to be instituted. To this end, radiographs and CT can be used, associated with biopsy (17), since the risks of performing it are minimal and far outweigh the consequences of an erroneous and inadequate diagnosis (12). Indeed, this is the benchmark pattern. However, the histopathological aspect of OS may resemble chondrosarcoma (9), fibrous dysplasias and other benign neoplasms. Yet, these lesions do not present an invasive infiltrate of malignant cells (1,18) and sometimes require other tests to confirm of the diagnosis made by means of (CT), accompanied or not by histopathological examination (9).

The immunohistochemical expression of p53, MDM2, PCNA and KI67 proteins contributes to establish the diagnosis of OS, as it showed prevalent positivity in 52% of cases for p53, 24% for MDM2, 84% for CDK4, 92% for PCNA, and 88% for KI67 in 25 head and neck OS (13).



RECIMA21 - REVISTA CIENTÍFICA MULTIDISCIPLINAR ISSN 2675-6218

IMPORTANCE OF THE CORRECT ASSOCIATION OF CLINICAL, IMAGINOLOGICAL AND HISTOPATHOLOGICAL EXAMS IN THE DIAGNOSIS OF OSTEOSARCOMA

Diego Leonardo de Souza, Victor Milis Wandelli, Cleomar Donizeth Rodrigues, Elimar Fernando Bauer, Luiz Carlos de Lima Dias Júnior, Fabiane Kellem Oliveira dos Santos Cesário, Virgílio Pimentel Galvão

In the case presented, three histopathological examinations were performed, the first of which was a leiomyoma of the oral mucosa, characterized by the absence of malignancy, and in the second, fibromatosis, with no features of malignancy. As the evolution of the clinical picture and the tomographic images were not compatible with the diagnosis of the histopathological exams performed, it was decided to perform a third histopathological exam. The inclusion of bone tissue in the biopsy of this third exam then made it possible to establish the diagnosis of OS. In the soft tissue, there was presence of a chronic inflammatory process with non-specific exacerbation in the mucosa and focal neoplastic infiltration. Further, a considerable number of cellular atypia were present, observed by cellular pleomorphism and altered nuclear morphology characterized by the variation of shape and size of cells and nuclei.

The type of extracellular matrix produced by tumor cells is of three histological types: osteoblastic, chondroblastic and fibroblastic, with chondroblastic being the most frequently found (8). This case is in disagreement, as the histopathological examination showed predominantly osteoblastic OS, with the presence of a nonspecific chronic inflammatory process in the mucosa and focal neoplastic infiltration. However, this case is consistent with another study which found that among 10 patients studied, 8 were of the osteoblastic type and 2 of the chondroblastic type (19).

Radiographically, OS appears as a destructive lesion with irregular edges that destroys the cortical bone and presents extra-osseous invasion. Varying amounts of calcification and mineralized bone are often present within the lesion. Periosteal reaction is often present and may present as "sunshine" (17). However, OS in the mandible can resemble benign pathologies of bone tissue, being difficult to associate with malignancies without other complementary exams (19). The appearance of "sun rays" is hardly seen on panoramic and periapical radiographs and, therefore, CT analysis is suggested for greater diagnostic contribution (20). This is what happened in the case presented; the initial panoramic radiograph of the patient showed an osteolytic lesion, only radiolucent with an irregular contour with small points of calcification. This was not enough to raise the hypothesis of OS considering that the radiographic appearance displayed included the differential diagnosis with chondrosarcoma (21), subacute osteomyelitis, active myositis ossificans, aneurysmal bone cyst, eosinophilic granuloma, Ewing's tumor, fibrosarcoma and metastatic carcinoma (17).

On helical CT, it is possible to evaluate soft and hard tissues, especially when contrast is used to delimit lesions involving soft tissues. This exam provides more detail in comparison with two-dimensional radiographs, as it allows visualization in three dimensions (20). On the patient's CT, it was possible to notice aggressive bone destruction with involvement of important structures such as the mental foramen and the mandibular canal on the left side, as well as involvement of the periapicals of teeth 33 and 35. This was in addition to the adjacent soft tissues, which were expanded and with bone spicules on the vestibular surface of the cortical bone, giving the image the appearance of "sun rays" due to the formation of osteoid tissue.



RECIMA21 - REVISTA CIENTÍFICA MULTIDISCIPLINAR ISSN 2675-6218

IMPORTANCE OF THE CORRECT ASSOCIATION OF CLINICAL, IMAGINOLOGICAL AND HISTOPATHOLOGICAL EXAMS IN THE DIAGNOSIS OF OSTEOSARCOMA
Diego Leonardo de Souza, Victor Milis Wandelli, Cleomar Donizeth Rodrigues, Elimar Fernando Bauer, Luiz Carlos de Lima Dias Júnior, Fabiane Kellem Oliveira dos Santos Cesário, Virgílio Pimentel Galvão

The patient underwent radical resection of the lesion with safety margins, as it is the most indicated treatment for patients with OS in the mandible (1,5,16,18). However, there was recurrence of the disease at the primary site, which is frequent according to the literature (6,14,15,22). Regarding chemotherapy and radiotherapy treatments associated or not with surgery, there are still many controversies due to the limited number of patients with OS in the mandible to carry out prospective studies (16). Radiotherapy is rarely used as an antineoplastic treatment for head and neck sarcomas due to its poor response to this treatment (17). Chemotherapy is usually used in patients who have had recurrence of the lesion after surgery as a perspective of reducing the size of the lesion or as an attempt to inhibit recurrence due to dubious surgical margins, although there is no effective evidence on the subject (23). In the present study, chemotherapy and radiotherapy were performed after the second surgery in order to verify the possibility of preventing the progression of the lesion and favoring a higher survival rate for the patient. However, these treatments were performed without success.

Survival rates in some studies have been 59% at 5 years, 49% at 10 years (13) and 2 to 5 years with or without relapse for other studies (2). The case reported in the present article exhibited a lower survival rate than that observed in most gnathic bone OS. The patient died 1 year after the lesion was noticed, which can partly be explained by the precious time lost with the erroneous diagnoses of the first two histopathological exams, but also by being an osteoblastic OS; in a study of 25 cases, patients with the chondroblastic variety had a higher survival rate when compared with the osteoblastic type (13). Recurrence generally decreases the survival rate at less than 5 years of follow-up (13). Six of the 14 patients followed for 2 to 6 months in one study had extensive recurrences and died (6), which also explains the short survival of the case presented here.

CONCLUSIONS

1. The radiographic and tomographic aspects of OS require a differential diagnosis whether accompanied by other neoplastic lesions or not. Its histopathological examination also presents similarity with other pathologies, and therefore the association of these tests with clinical findings is necessary to establish the diagnosis. In this case, the perception that the clinical evolution and aspects of the tomographic images were not compatible with the histopathological results, and the decision to include bone tissue in the third biopsy, were crucial to reach the definitive diagnosis.

2. In malignant neoplasms, early diagnosis and treatment are essential for their eradication or for the patient's survival time. In the case of this study, the time spent waiting for two (inconclusive) histopathological exams delayed the start of treatment, which may have affected the patient's survival.

3. The patient's dental follow-up was critical to reach the correct diagnosis of OS. However, with it being a fast-progressing lesion that did not respond adequately to the treatments used, the patient died in a short period of time. Further studies are needed to seek protocols that both



RECIMA21 - REVISTA CIENTÍFICA MULTIDISCIPLINAR ISSN 2675-6218

IMPORTANCE OF THE CORRECT ASSOCIATION OF CLINICAL, IMAGINOLOGICAL AND HISTOPATHOLOGICAL EXAMS IN THE DIAGNOSIS OF OSTEOSARCOMA

Diego Leonardo de Souza, Victor Milis Wandelli, Cleomar Donizeth Rodrigues, Elimar Fernando Bauer, Luiz Carlos de Lima Dias Júnior, Fabiane Kellem Oliveira dos Santos Cesário, Virgílio Pimentel Galvão

accelerate the definitive diagnosis and establish efficient treatment alternatives for OS. In turn, this will improve survival rates as well as the patient's quality of life.

REFERENCES

1. Valente R, Abreu TC, REAL FH. Osteosarcoma in the Mandible-Case report. Revista de Cirurgia e Traumatologia Buco-Maxilo-Facial. 2011 Out/Dez;11(4):37-42.
2. Araujo JP. Estudo epidemiológico, clínico e imaginológico das lesões ósseas dos maxilares. [Dissertação Mestrado]; São Paulo: Universidade de São Paulo; 2015. 70 p.
3. Alqahtani D, Alsheddi M, Al-Sadhan R. Epithelioid Osteosarcoma of the Maxilla. International Journal Of Surgical Pathology 2015. Jun;23(6):495-499.
4. Tran LM, Mark R, Meier R, Calcaterra TC., Parker RG. Sarcomas of the head and neck. Prognostic factors and treatment strategies. Cancer. 1992. Jul;70(1):169-177.
5. Lukschal LF, Barbos RMLB, Alvarenga RL, Horta MCR. Osteossarcoma em maxila: relato de caso. Revista Portuguesa de Estomatologia, Medicina Dentária e Cirurgia Maxilofacial. 2013 Jan;54(1):48-52.
6. Chindia ML, Guthua SW, Awange DO, Wakoli KA. Osteosarcoma of the maxillofacial bones in Kenyans J Maxillofac Surg. 2002;26(2):98-101.
7. Olavez D, Florido R, Padrón K, Omaña C, Solózano E. Maxillary osteosarcoma. Histopathologic case report. Acta bioclínica. 2012;2(3):14-25.
8. Lee YY, Tassel PV, Nauert C, Raymond AK, Edeiken J. Craniofacial osteosarcoma-plain film ct, and mr findings in 46 cases. American journal of neuroradiology. 1988;(9):379-385.
9. Tossato OS, Pereira AC, Cavalcanti MPG. Osteossarcoma e condrossarcoma: diferenciação radiográfica por meio da tomografia computadorizada. Pesquisa Odontológica Brasileira. 2002. Mar;16(1):69-76.
10. Cavalcanti MGP, Ruprecht A, Quest J. Evaluation of maxillofacial fibrosarcoma using computer graphics and spiral computed tomography. Dentomaxillofac Radiol. 1999.Mai.28(3):145-151.
11. Chrcanovic BR, Sousa, LN. A importância do diagnóstico diferencial entre o osteossarcoma de baixo grau e a displasia fibrosa – Revisão de literatura. Arquivo Brasileiro de Odontologia. 2012;8(2):55-62.
12. Caubi AF, Xavier RLF, Lima Filho MA, Chalegre JF. Bópsia. Revista de Cirurgia e Traumatologia Buco-Maxilo-Facial. 2004 Jan/Mar;4(1):39-46.
13. Takahama Júnior A, Alves FA, Pinto CAL, Carvalho AL, Kowalski LP, Lopes MA. Clinicopathological and immunohistochemical analysis of twenty-five head and neck osteosarcomas Oral Oncol. 2003;39(5):521-30.
14. Mardinger O, Givol N, Talmi YP, Taicher S, Saba K. Osteosarcoma of the jaw Oral Med Oral Pathol Oral Radiol Endod. 2001;91:445-51.



RECIMA21 - REVISTA CIENTÍFICA MULTIDISCIPLINAR ISSN 2675-6218

IMPORTANCE OF THE CORRECT ASSOCIATION OF CLINICAL, IMAGINOLOGICAL AND HISTOPATHOLOGICAL EXAMS IN THE DIAGNOSIS OF OSTEOSARCOMA

Diego Leonardo de Souza, Victor Milis Wandelli, Cleomar Donizeth Rodrigues, Elimar Fernando Bauer, Luiz Carlos de Lima Dias Júnior, Fabiane Kellem Oliveira dos Santos Cesário, Virgílio Pimentel Galvão

15. Bennet JH, Thomas G, Evans AW, Speight PM. Osteosarcoma of the jaws: A 30-year retrospective review. *Oral Surg Oral Med Oral Pathol.* 2000;90(3):323-33.
16. Soares RC, Soares AF, Souza LB, Santos ALV, Pinto LP. Osteossarcoma de mandíbula inicialmente mimetizando lesão do periápice dental: relato de caso. *Revista Brasileira de Otorrinolaringologia.* 2005 abr;71(2):242-245.
17. Angel EE, Gava NF. Tumores Ósseos: Princípios de Diagnóstico e Tratamento. Ribeirão Preto: USP; 2012. 29p.
18. Ribeiro ALR, Nobre RM, Alves Junior SMA, Silva e Souza PAR; Silva Junior NGS, Pinheiro JJV. The importance of early diagnosis and an accurate tumoral evaluation in the treatment of mandibular osteossarcoma. *Rev. Odonto Ciênc.* 2010;Jun;25(3):319-324.
19. Nakayama E, Sugiura K, Kobayashi I, Oobu Ki, Ishibashi H, Kanda S. The association between the computed tomography findings, histologic features, and outcome of osteosarcoma of the jaw. *Journal Of Oral And Maxillofacial Surgery.* 2005. Mar;63(3):311-318.
20. Ng SY, Songra A, Ali N, Carter JLB. Ultrasound features of osteosarcoma of the mandible—a first report. *Oral Surgery, Oral Medicine, Oral Pathology, Oral Radiology, And Endodontology.* 2001 Nov;92(5):582-586.
21. Loureiro BMC, Altemani JMC, Reis F, Altemani AMAM. Osteossarcoma crâniofacial: um enfoque imagenológico. *Revista Brasileira de Odontologia.* 2017 Jun;74(2):176.
22. Castro HC, Ribeiro KCB, Bruneira P. Osteossarcoma: experiência do serviço de oncologia pediátrica da Santa Casa de Misericórdia de São Paulo. *Revista Brasileira de Ortopedia.* 2008 abr;43(4):108-115.
23. Rosenthal MA, Mougos S, Wiesenfeld D. High-grade maxillofacial osteosarcoma: evolving strategies for a curable cancer. *Oral Oncology.* 2003 jun;9(4):402-404.