

**THE USE OF MINI-IMPLANTS FOR UPPER INCISORS ORTHODONTIC INTRUSION: A BRIEF LITERATURE REVIEW****A UTILIZAÇÃO DE MINI-IMPLANTES PARA A INTRUSÃO ORTODÔNTICA DOS INCISIVOS SUPERIORES: UMA BREVE REVISÃO DA LITERATURA****EL USO DE MINIIMPLANTES PARA LA INTRUSIÓN ORTODÓNICA DE LOS INCISIVOS SUPERIORES: BREVE REVISIÓN BIBLIOGRÁFICA**Kerllen Dayane Barbosa Alves<sup>1</sup>, Mayra Fernanda Ferreira<sup>1</sup>, Marcos Rogério de Mendonça<sup>1</sup>

e595739

<https://doi.org/10.47820/recima21.v5i9.5739>

RECEIVED: 08/12/2024

APPROVED: 09/12/2024

PUBLICADO: 09/27/2024

**RESUMO**

A intrusão refere-se ao movimento de um dente ao longo de seu longo eixo para dentro do alvéolo, uma técnica necessária em certos tratamentos ortodônticos para a correção da sobremordida. Entretanto, esse movimento é notoriamente difícil de ser obtido e medido. O advento dos mini-implantes como sistemas de ancoragem esquelética simplificou significativamente o processo. Esse estudo tem como objetivo revisar a literatura sobre o uso de mini-implantes para intrusão de incisivos como tratamento para sobremordida. Os mini-implantes oferecem várias vantagens, incluindo a facilidade de instalação e remoção, a versatilidade dos locais de implantação, o baixo custo, a capacidade de aplicar força imediata e a independência da cooperação do paciente. Esses benefícios tornam os mini-implantes uma alternativa eficaz para a ancoragem esquelética em ortodontia.

**PALAVRAS-CHAVE:** Mini-implante. Sobremordida. Procedimentos de Ancoragem Ortodôntica. Aparelhos Ortodônticos.

**ABSTRACT**

Intrusion refers to the movement of a tooth along its long axis into the socket, a technique required in certain orthodontic treatments for overbite correction. However, this movement is notoriously difficult to achieve and measure. The advent of mini-implants as skeletal anchorage systems has significantly simplified the process. This study aims to review the literature on using mini-implants for incisor intrusion as a treatment for overbite. Mini-implants offer several advantages, including easy installation and removal, versatility in implantation sites, low cost, the ability to apply immediate force, and independence from patient cooperation. These benefits make mini-implants an effective alternative for skeletal anchorage in orthodontics.

**KEYWORDS:** Mini-implant. Overbite. Orthodontic Anchorage Procedures. Orthodontic Appliances.

**RESUMEN**

La intrusión se refiere al movimiento de un diente a lo largo de su eje largo dentro del alveolo, una técnica necesaria en ciertos tratamientos de ortodoncia para corregir la sobremordida. Sin embargo, este movimiento es notoriamente difícil de obtener y medir. La llegada de los miniimplantes como sistemas de anclaje esquelético ha simplificado considerablemente el proceso. Este estudio pretende revisar la literatura sobre el uso de miniimplantes para la intrusión incisiva como tratamiento de la sobremordida. Los miniimplantes ofrecen varias ventajas, como la facilidad de colocación y retirada, la versatilidad de los lugares de implantación, el bajo coste, la posibilidad de aplicar fuerza inmediata y la independencia de la cooperación del paciente. Estas ventajas hacen de los miniimplantes una alternativa eficaz para el anclaje esquelético en ortodoncia.

**PALABRAS CLAVE:** Miniimplante. Sobremordida. Procedimientos de anclaje ortodôntico. Aparatos de ortodoncia.

<sup>1</sup> Faculdade de Odontologia de Araçatuba, FOA -UNESP, Brazil.



## RECIMA21 - REVISTA CIENTÍFICA MULTIDISCIPLINAR ISSN 2675-6218

THE USE OF MINI-IMPLANTS FOR UPPER INCISORS ORTHODONTIC INTRUSION: A BRIEF LITERATURE REVIEW  
Kerllen Dayane Barbosa Alves, Mayra Fernanda Ferreira, Marcos Rogério de Mendonça

### 1. INTRODUCTION

Overbite (OB) is a complex orthodontic issue involving teeth, alveolar bone, mandible, maxilla, and soft tissues of the face (Nielsen, 1991; Fuiziy *et al.*, 2015; Sosly *et al.*, 2020). Its correction requires a thorough diagnostic analysis, an individualized treatment plan, and careful selection of the appropriate treatment method (Nielsen, 1991; Fuiziy *et al.*, 2015). In normal occlusion, the upper central incisors gently overlap the lower incisors, measured in millimeters or as a percentage of the lower incisor's crown (Nielsen, 1991). When OB is severe, it leads to periodontal tissue destruction, upper anterior teeth migration, and lower incisors wear (Nielsen, 1991; Fuiziy *et al.*, 2015). Correcting OB is essential when it impacts facial aesthetics and dental health (Nielsen, 1991; Brito *et al.*, 2009; Kaushik *et al.*, 2015; Fuiziy *et al.*, 2015; Sosly *et al.*, 2020).

Intrusion, the movement of a tooth into the alveolus along its long axis, is a critical and challenging orthodontic movement necessary for OB correction (Kaushik *et al.*, 2015; Sosly *et al.*, 2020). The main indications for maxillary anterior teeth intrusion are: 1) correcting OB in hyperdivergent cases with Class II malocclusion in patients with completed mandibular growth (Burstone, 1977); 2) compensating for maxillary incisors extrusion in gummy smile cases and poor lip seal (Cruz; Munõz, 2010; Ghafari *et al.*, 2013; Varlik *et al.*, 2013); 3) aiding restorative treatments in cases of irregular gingival margins and worn incisal edges (Bellamy *et al.*, 2008); and 4) combined with surgical periodontal treatment for incisor migration and extrusion due to periodontal disease (Nasry; Barclay, 2006).

Anatomical limitations, such as the 1mm space between the root apex and the alveolar bone's deepest part, must be considered before intrusion (Janson *et al.*, 2006; Araújo *et al.*, 2008; Gracco *et al.*, 2011). Biomechanical limitations also pose challenges, as intrusive forces create a moment that can cause tooth tilting and undesirable movements in the dental arch (Gracco *et al.*, 2011). Intrusion requires significant bone resorption and progresses slowly at a rate of approximately 0.3mm per month (Gracco *et al.*, 2011).

Several therapeutic methods for OB correction exist intrusion (Janson *et al.*, 2006; Araújo *et al.*, 2008; Gracco *et al.*, 2011). The Ricketts utility arch can intrude incisors but tends to cause vestibularization and occlusal plane rotation. The Burstone segmented arch, a 3-piece system, offers better intrusion qualities with fewer side effects (Gracco *et al.*, 2011). The continuous arch alignment and leveling system, using curvatures like the steep and reverse curve of Spee, combines incisor intrusion with molar extrusion but has the drawback of buccalization and slow results (Gracco *et al.*, 2011).

A common challenge with all these systems is the reaction force causing extrusion of the supporting teeth (Janson *et al.*, 2006; Araújo *et al.*, 2008; Gracco *et al.*, 2011). The use of mini-implants (MIs) as skeletal anchorage systems has significantly mitigated these issues, offering advantages such as immediate loading, multiple implantation sites, simple placement and removal, low cost, and independence from patient cooperation (Janson *et al.*, 2006). The aim of this brief



## RECIMA21 - REVISTA CIENTÍFICA MULTIDISCIPLINAR ISSN 2675-6218

THE USE OF MINI-IMPLANTS FOR UPPER INCISORS ORTHODONTIC INTRUSION: A BRIEF LITERATURE REVIEW  
Kerllen Dayane Barbosa Alves, Mayra Fernanda Ferreira, Marcos Rogério de Mendonça

literature review is to present the use of IMs as a means of anchorage for incisor intrusion as one of the treatment methods for overbite.

### 2. BRIEF LITERATURE REVIEW

Ohnishi *et al.*, (2005) presented a case involving a 19-year-old patient with anterior crowding, a vertical trespass (VT) of 7.2 mm, and a horizontal trespass (TH) of 4.8 mm (Ohnishi *et al.*, 2005). The treatment plan aimed to intrude the maxillary incisors using a mini-implant (MI) for orthodontic anchorage (Ohnishi *et al.*, 2005). The MI was 6 mm in length and 1.2 mm in diameter, placed in the alveolar bone between the root apices of the maxillary central incisors (Ohnishi *et al.*, 2005). A light force of 20g was maintained for 15 months (Ohnishi *et al.*, 2005). The upper incisors were intruded by approximately 4 mm, and after 21 months, the VT improved to 1.7 mm and the TH to 2.6 mm. Post-treatment records confirmed no root resorption, an improved gingival smile, and Class I molar and canine relationships (Ohnishi *et al.*, 2005).

Kim *et al.*, (2006) reported on a 10-year-old male with Class II division 2 malocclusion, dental crowding, and a gummy smile (Kim *et al.*, 2006). Treatment involved using an MI with segmented wires, resulting in 4 mm of maxillary incisor intrusion (Kim *et al.*, 2006). The gummy smile was corrected, and the Class II division 2 pattern changed to Class II division 1 (Kim *et al.*, 2006). Total treatment time was 2 years and 3 months, achieving overcorrected Class I canine and molar relationships. The MI was stable and well-tolerated throughout the treatment (Kim *et al.*, 2006).

Polat-Ozsoy *et al.*, (2011) compared the effects of incisor intrusion using MIs versus base arches in a sample of 24 patients (Polat-Ozsoy *et al.*, 2011). The MI group showed an intrusion rate of 0.44 mm per month and achieved 2.97 mm of maxillary incisor intrusion, while the base arch group had an intrusion rate of 0.27 mm per month and achieved 1.81 mm (Polat-Ozsoy *et al.*, 2011). The MI group exhibited true intrusion of 1.75 mm with minimal protrusion and no root resorption, highlighting the efficacy of MIs over utility arches for incisor intrusion (Polat-Ozsoy *et al.*, 2011).

Senisik and Turkkahraman (2012) evaluated the efficiency of maxillary incisor intrusion using MIs and intrusion archwires in 45 patients with Class II division 2 malocclusion (Senisik; Turkkahraman, 2012) The MI group achieved an average pure intrusion of 2.47 mm, slightly higher than the 2.20 mm achieved by the intrusion arch group (Senisik; Turkkahraman, 2012). Both systems led to protrusion and intrusion of the upper incisors (Senisik; Turkkahraman, 2012). The study concluded that MIs provide sufficient anchorage for effective upper incisor intrusion, with a 90% success rate (Senisik; Turkkahraman, 2012).

Uzuka *et al.*, (2018) treated a 27-year-old woman with diastemas and a gummy smile caused by vertical maxillary excess (Uzuka *et al.*, 2018) The treatment involved using multiple MIs for maxillary incisor and molar intrusion (Uzuka *et al.*, 2018). Over 3 years and 6 months, the treatment achieved approximately 5 mm of incisor intrusion and 1.5 mm of molar intrusion (Uzuka *et al.*, 2018). The gingival smile and diastemas were significantly improved, and stable occlusion was maintained



## RECIMA21 - REVISTA CIENTÍFICA MULTIDISCIPLINAR ISSN 2675-6218

THE USE OF MINI-IMPLANTS FOR UPPER INCISORS ORTHODONTIC INTRUSION: A BRIEF LITERATURE REVIEW  
Kerllen Dayane Barbosa Alves, Mayra Fernanda Ferreira, Marcos Rogério de Mendonça

post-treatment (Uzuka *et al.*, 2018). Despite signs of apical root resorption in the anterior teeth, no significant bone resorption was observed (Uzuka *et al.*, 2018).

The discussed studies and case reports demonstrate the effectiveness of mini-implants (MIs) in correcting overbites through maxillary incisor intrusion. MIs provide stable anchorage, minimize side effects such as root resorption and protrusion, and lead to significant improvements in gingival smiles and overall dental aesthetics. These findings support the preference for MIs over traditional methods for overbite correction.

### 3. FINAL CONSIDERATIONS

#### 3.1. Mini-Implants and the intrusion of upper incisors in the treatment of overbite

This chapter was written with the aim of presenting the method of intrusion of upper incisors supported by IM.

##### 3.1.1. Anatomy of the mini-implant

Also known as a temporary anchorage device (TAD), MIs for orthodontic purposes are designed to be removed after the end of treatment, consequently they are functional for a relatively short time compared to endosseous implants used in dental rehabilitation. They are produced in titanium with different degrees of purity and surface treatment and can vary from 4 to 12mm in length with a diameter of 1.2 to 2mm and a self-drilling or self-tapping thread format (Proffit *et al.*, 2007). The self-tapping IM has cutting power and after the initial osteotomy with a milling cutter creates its entry path into the bone. Self-piercing MIs do not require bone milling and have a simpler and quicker operative process.

Despite the different designs, shapes and sizes, which vary according to the commercial brand, it is possible to divide the constitution of MI into three distinct parts: A) head, B) transmucosal profile and C) active tip (Fig. 1).



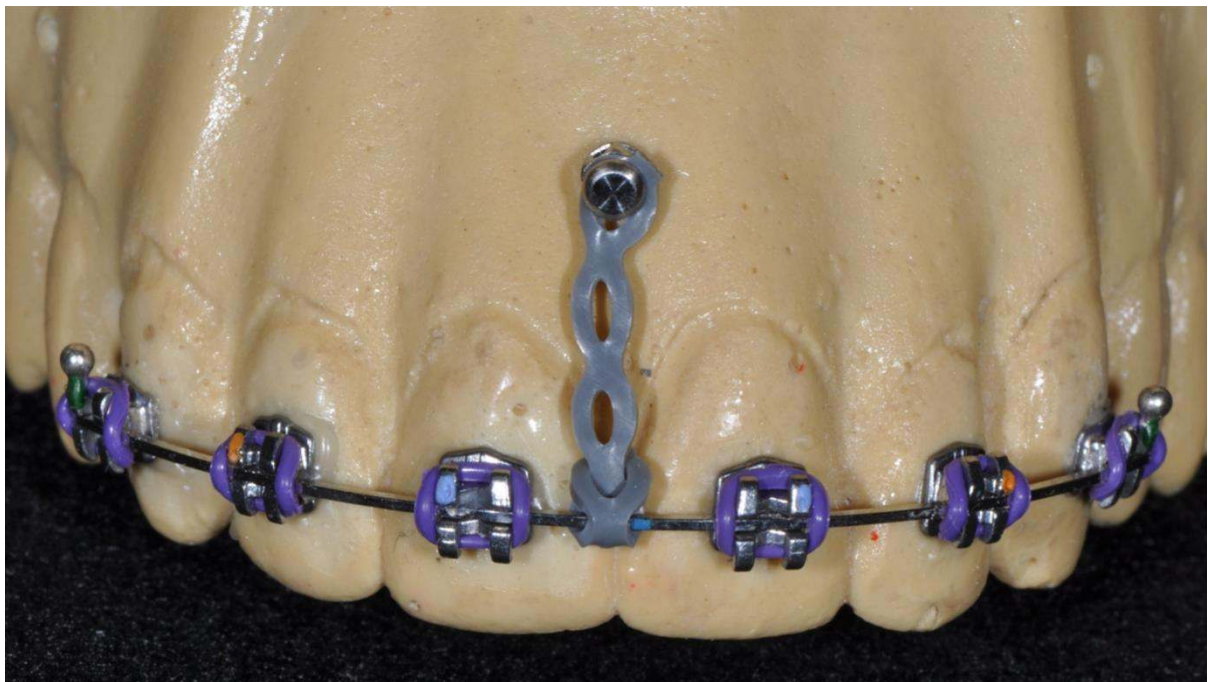
**Figure 1.** A close-up view of a mini-implant  
Source: The authors

The implant head is the clinically exposed part where orthodontic devices such as elastics, springs and wires are attached. The transmucosal profile is the area between the intraosseous portion and the MI head, where the peri-implant soft tissue is accommodated. The active tip is the intraosseous portion corresponding to the implant threads.

### 3.2. Insertion Site

#### 3.2.1. Midline

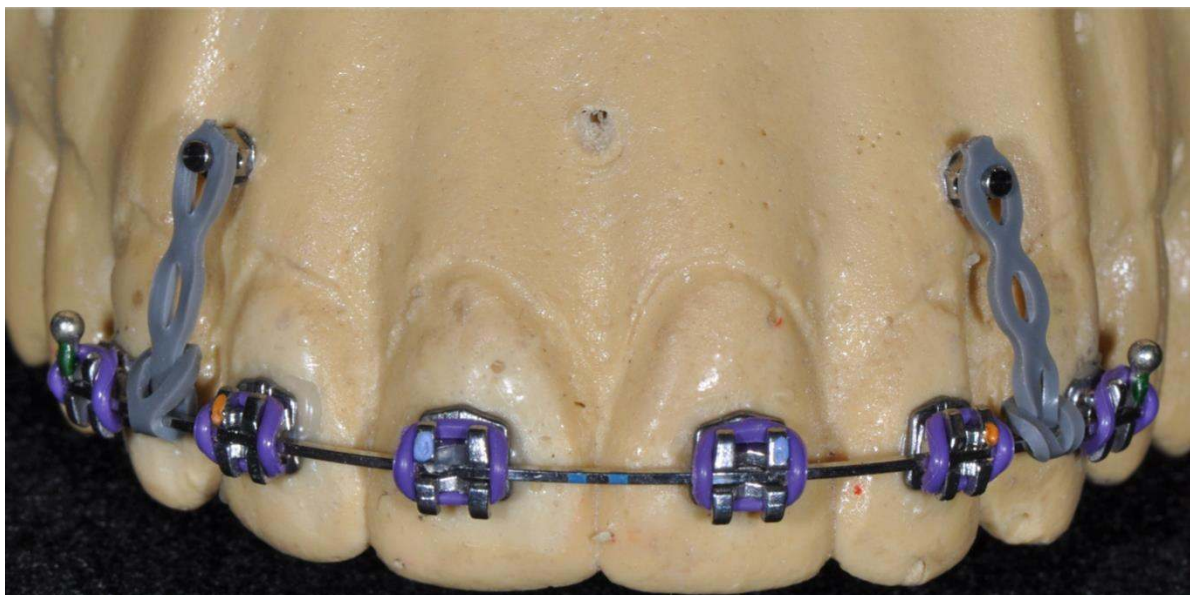
For cases where control of incisor buccalization is not critical, limited intrusion (Fig. 2).



**Figure 2.** Mini-implant inserted in the midline  
 Source: The authors

#### 3.2.2. Between lateral incisor and canine

For cases where control of incisor buccalization is critical, intrusion of all six anterior teeth (Fig. 3).



**Figure 3.** Mini-implants installed between lateral incisors and canines  
Source: The authors

For the incisor intrusion movement, the MI placed buccally between the roots of the canines and lateral incisors (bilaterally) in the maxilla or mandible must have a length of 6mm and a diameter of 1.2 to 1.8mm, and the same characteristics when placed between the roots of the incisors (Garbin *et al.*, 2016).

### 3.3. Insertion Guide

For the surgeon's guidance, an insertion guide can be made with brass wire (0.6mm thick) passing through the point of contact between the dental structures, extending in an apical direction. The radiopaque image of the guide, visualized on the periapical radiograph, serves as a reference for the correct positioning of the mini-implant.

### 3.4. Insertion Height

Insertion should be carried out taking as a reference the muco-gingival limit, a line that determines the boundary between the inserted gingiva and the alveolar mucosa. The MI should be inserted over this line or within a margin of up to 2mm above it.

Insertion too far below this line has the limiting factors of a reduced amount of alveolar bone, an increased chance of MI loss, and a very low force application system.

On the other hand, insertion too far above this line has the limiting factors of the possibility of the MI being covered by the gingival mucosa, difficulty in sanitizing, and the force application system being too high.



## RECIMA21 - REVISTA CIENTÍFICA MULTIDISCIPLINAR ISSN 2675-6218

THE USE OF MINI-IMPLANTS FOR UPPER INCISORS ORTHODONTIC INTRUSION: A BRIEF LITERATURE REVIEW  
Kerllen Dayane Barbosa Alves, Mayra Fernanda Ferreira, Marcos Rogério de Mendonça

### 3.5. Asepsis

This procedure is common to all clinical procedures involving soft tissue invasion. The recommended method is 2% chlorhexidine mouthwash.

### 3.6. Anesthesia

Topical anesthetic and superficial local anesthesia are used for gingival anesthesia.

### 3.7. Fitting

Before the MI is placed, it is necessary to assess whether there is sufficient interdental bone by means of imaging tests, as the stability of the MI is conferred by the contact surface with the bone, so the thicker the cortical bone, the better the stability. The inclination of the incisors should also be analyzed in order to find the ideal position for the MI (Janson *et al.*, 2006). ICMs can be inserted into the alveolar bone using short or long hand wrenches, or mechanical wrenches coupled to the surgical motor at low speed (20 rpm) with irrigation to prevent bone heating (Araújo *et al.*, 2008).

### 3.8. Force Application Systems

There are two basic mechanisms for intrusion using MI: direct and indirect anchorage (Cruz *et al.*, 2010). In direct anchorage, a single, direct force is applied to the implant, which can produce an uncontrolled inclination and is therefore viable when only the incisors are to be intruded and they are lingualized (Cruz *et al.*, 2010). For indirect anchorage, the MI is incorporated into the anchorage unit of intrusion arches and continuous arch systems, controlling reaction forces and their side effects (Cruz *et al.*, 2010).

## 4. DISCUSSION

The general dental surgeon must know the principles of ideal occlusion in order to be able to diagnose when a malocclusion is present (Nielsen *et al.*, 1991; Brito *et al.*, 2009; Kaushik *et al.*, 2015; Sosly *et al.*, 2020). DP is a vertical malocclusion that is very common in adult and child malocclusions and can manifest itself in Class I, II and III in the deciduous, mixed and permanent dentition periods (Nielsen *et al.*, 1991; Brito *et al.*, 2009; Kaushik *et al.*, 2015; Sosly *et al.*, 2020). An epidemiological survey of students in the municipal school system in the city of Araraquara-SP showed that 26.63% of children aged between 5 and 12 had PM, 24.09% in the 5 to 8 age group and 31.78% in the 9 to 12 age group (Boeck *et al.*, 2013).

As this is such a frequent problem, general practitioners may come across this malocclusion at some point in their dental practice and, in order to correctly diagnose and indicate treatment, they must know its etiology in order to avoid and/or reduce the damage caused by this malocclusion (Boeck *et al.*, 2013). Considering this information and taking it from the point of view of dental practice, this leads us to think about continuing training to be able to offer treatment to these patients,



## RECIMA21 - REVISTA CIENTÍFICA MULTIDISCIPLINAR ISSN 2675-6218

THE USE OF MINI-IMPLANTS FOR UPPER INCISORS ORTHODONTIC INTRUSION: A BRIEF LITERATURE REVIEW  
Kerlen Dayane Barbosa Alves, Mayra Fernanda Ferreira, Marcos Rogério de Mendonça

as well as establishing partnerships with specialists who are available to see these patients on a percentage basis (Boeck *et al.*, 2013).

OB is considered difficult to treat successfully due to its multifactorial origin, so a correct diagnosis is essential for successful and stable treatment (Brito *et al.*, 2009). The interpretation of facial, cephalometric and dental analyses are important factors in obtaining a diagnosis and an individualized treatment plan for the patient (Brito *et al.*, 2009). The anatomical and biomechanical limitations are important factors to be considered for the therapeutic procedure of incisor intrusion and, in addition, the patient's facial and dental characteristics must be observed for the correct indication of this treatment (Ohnishi *et al.*, 2005; Kim *et al.*, 2006; Janson *et al.*, 2006; Gracco *et al.*, 2011). The level of gingival exposure should be assessed during smiling and speaking, and the relationship of the upper lip to the upper incisors during rest (NASRY & BARCLAY, 2006). This information can be analyzed clinically in a frontal and lateral view, and by means of lateral teleradiography (Nasry; Barclay, 2006; Brito *et al.*, 2009). According to the literature, the appropriate smile relationship varies from a position where the upper lip rests on the gingival margin of the upper central incisors to a position where 2mm of gingival exposure is observed (Brito *et al.*, 2009, Fuiziy *et al.*, 2015; Ghafari *et al.*, 2013). Thus, the intrusion of upper incisors is indicated when patients have a gummy smile, lack of lip seal, short upper lip, increased lower facial height and an excessively inclined occlusal plane (Brito *et al.*, 2009, Fuiziy *et al.*, 2015; Ghafari *et al.*, 2013).

The use of MIs as anchorage for intrusive movements makes it possible to control the side effects of anchorage that occur in the mechanics of intrusion arches, as the teeth are protected from any unwanted movement (Janson *et al.*, 2006; Araújo *et al.*, 2008, Gracco *et al.*, 2011). The additional advantages of MIs as skeletal anchorage are that their installation and removal are simple, immediate force can be applied, multiple implantation sites, low cost, no need for patient cooperation and the use of light and continuous forces has shown a low rate of apical resorption (Cruz *et al.*, 2010).

### 5. CONCLUSION

Based on the articles analyzed in this review, we can conclude that:

- The intrusion of the upper incisors anchored on mini-implants is a favorable procedure for the correction of deep bite;
- The use of mini-implants as anchorage is an effective alternative for the treatment of deep bite, as it offers more versatility for the orthodontic mechanics involved in the intrusion process;
- The advantages of this approach are the reduction of unwanted side effects which suggests a more controlled tooth movement.

### REFERENCES

ARAÚJO, T. M.; ALMEIDA, R. C.; ARAÚJO, N. S.; CAMARGOS, G. V. Intrusão dentária utilizando mini-implantes. **R Dental Press Ortodon Ortop Facial**, v. 13, n. 5, p. 36-48, 2008.



## RECIMA21 - REVISTA CIENTÍFICA MULTIDISCIPLINAR ISSN 2675-6218

THE USE OF MINI-IMPLANTS FOR UPPER INCISORS ORTHODONTIC INTRUSION: A BRIEF LITERATURE REVIEW  
Kerllen Dayane Barbosa Alves, Mayra Fernanda Ferreira, Marcos Rogério de Mendonça

BELLAMY, L. J.; KOKICH, V. G.; WEISSMAN, J. A. Using orthodontic intrusion of abraded incisors to facilitate restoration: The technique's effects on alveolar bone level and root length. **JADA**, v. 139, n. 6, p. 725-733, 2008.

BOECK, E. M.; PIZZOL, K. E. D. C.; NAVARRO, N.; CHIOZZINI, N. M.; FOSCHINI, A. L. R. Prevalência de malocclusão em escolares de 5 a 12 anos de rede municipal de ensino de Araraquara. **Rev CEFAC**, v. 15, n. 5, p. 1270-1280, 2013.

BRITO, H. H. A.; LEITE, H. R.; MACHADO, A. W. Sobremordida exagerada: diagnóstico e estratégias de tratamento. **R Dental Press Ortodon Ortop Facial**, v. 14, n. 3, p. 128-157, 2009.

BURSTONE, C. R. Deep overbite correction by intrusion. **Am J Orthod**, v. 72, n. 1, p. 1-22, 1977.

CRUZ, B. M.; MUÑOZ, C. E. Tratamiento ortodóncico de mordidas profundas. **Rev Fac Odontol Univ Antioq**, v. 23, n. 1, p. 158-173, 2010.

FUIZIY, A.; KINOSHITA, D.; HENRIQUES, J. F. C.; JANSON, G.; CANCADO, R. H. Considerações sobre a etiologia, o diagnóstico e tratamento da sobremordida profunda. **Rev Clín Ortod Dental Press**, v. 14, n. 3, p. 6-36, 2010.

GARBIN, A. J. I.; GRIECO, F. A. D.; ROSSI, L. B. **Ancoragem Ortodôntica Placas e Mini-implantes**: Ortodontia de visão. Ribeirão Preto: Tato, 2016.

GHAFFARI, J. G.; MACARI, A. T.; HADDAD, R. V. Overbite: Treatment options and challenges. **Semin Orthod**. v. 19, n. 4, p. 253-266, 2013.

GRACCO, A.; TRACEY, S.; LOMBARDO, L.; SICILIANI, G. Upper incisor intrusion: An anatomical analysis via CBCT. **Int Orthod**. v. 9, p. 210-223, 2011.

JANSON, M.; VALLEJO-LINARES, L.; CAFFERATA, E. A.; CANUTO, C. E.; GARIB, D. G. Ancoragem esquelética com mini-implantes: incorporação rotineira da técnica na prática ortodôntica. **Rev Clín Ortod Dental Press**, v. 5, n. 4, p. 85-100, 2006.

KAUSHIK, A.; SIDHU, M.; GROVER, S.; KUMAR, S. Comparative evaluation of intrusive effects of miniscrew, Connecticut intrusion arch, and utility intrusion arch—an in vivo study. **Journal of Pierre Fauchard Academy**, (India Section), v. 29, p. 69–76, 2015.

KIM, T. W.; KIM, H.; LEE, S. J. Correction of deep overbite and gummy smile by using a mini-implant with a segmented wire in a growing Class II Division 2 patient. **Am J Orthod Dentofacial Orthop**, v. 130, n. 5, p. 676-685, 2006.

NASRY, H. A.; BARCLAY, S. C. Periodontal lesions associated with deep traumatic overbite. **Br Dent J**, v. 200, n. 10, p. 557-561, 2006.

NIELSEN, I. L. Vertical malocclusions: etiology, development, diagnosis and some aspects of treatment. **Angle Orthod.**, v. 61, p. 247–260, 1991.

OHNISHI, H.; YAGI, T.; YASUDA, Y.; TAKADA, K. A Mini-Implant for Orthodontic Anchorage in a Deep Overbite Case. **Angle Orthod**, v. 75, n. 3, p. 444-452, 2005.

POLAT-OZSOY, O.; ARMAN-OZCIRPICI, A.; VEZIROGLU, F.; KAMAK, H. Comparison of the intrusive effects of miniscrews and utility arches. **Am J Orthod Dentofacial Orthop.**, v. 139, n. 4, p. 526-532, 2011.

PROFFIT, W. R.; FIELDS, H. W.; SARVER, D. M. **Ortodontia contemporânea**. Rio de Janeiro: Elsevier, 2007.



**RECIMA21 - REVISTA CIENTÍFICA MULTIDISCIPLINAR**  
**ISSN 2675-6218**

THE USE OF MINI-IMPLANTS FOR UPPER INCISORS ORTHODONTIC INTRUSION: A BRIEF LITERATURE REVIEW  
Kerllen Dayane Barbosa Alves, Mayra Fernanda Ferreira, Marcos Rogério de Mendonça

SENISIK, N. E.; TURKKAHRAMAN, H. Treatment effects of intrusion arches and mini-implant systems in deepbite patients. **Am J Orthod Dentofacial Orthop**, v. 141, n. 6, p. 723-733, 2012.

SOSLY, R.; MOHAMMED, H.; RIZK, M. Z.; JAMOUS, E.; QAISI, A. G.; BEARN, D. R. Effectiveness of miniscrew-supported maxillary incisor intrusion in deep-bite correction: A systematic review and meta-analysis. **Angle Orthod**, v. 90, n. 2, p. 291-304, 2020.

UZUKA, S.; HARA, S.; MURATA, Y.; ITANI, Y. Adult gummy smile correction with temporary skeletal anchorage devices. **J World Fed Orthod**, v. 7, p. 34-46, 2018.

VARLIK, S. K.; GULTAN, A.; KURT, G. Deepbite correction with incisor intrusion in adults: A long-term cephalometric study. **Am J Orthod Dentofacial Orthop**, v. 144, n. 3, p. 414-419, 2013.