v7.n11.2026

SCIENTIFIC JOURNAL - RECIMA21 ISSN 2675-6218

EFFECTS OF ENDOLASER IN THE TREATMENT OF SAGGING SKIN IN THE LOWER THIRD OF THE FACE AND NECK

EFEITOS DO ENDOLASER NO TRATAMENTO DA FLACIDEZ DO TERÇO INFERIOR DA FACE E DO PESCOÇO

EFECTOS DEL ENDOLÁSER EN EL TRATAMIENTO DE LA FLACIDEZ CUTÁNEA EN EL TERCIO INFERIOR DEL ROSTRO Y EL CUELLO

Amanda Rodrigues Costa[1], Anna Cecília Dias Maciel Carneiro[2], Marco Túlio Rodrigues da Cunha[3], Sheila Clemente Mendonça D'Aloia[4], Suzana Fontanetti[5], Mariana Molinar Mauad Cintra[6], Osmar José Ferreira[7], Adriana Clemente Mendonça[8]

e7119346

https://doi.org/10.47820/recima21.v7i11.9346

PUBLISHED: 11/2026

ABSTRACT

Facial rejuvenation has traditionally relied on invasive surgical procedures. Endolaser is a minimally invasive technique that may improve skin laxity through connective tissue remodeling and collagen stimulation. This study aimed to evaluate the effects of endolaser on skin laxity in the lower third of the face, submental region, and neck, and to investigate associations between treatment outcomes and participants' age. This longitudinal, quasi-experimental case series included ten volunteers (mean age: 50.7 ± 7.21 years) and blinded evaluators. Participants underwent a single session using the Delight® 1470 nm diode laser in pulsed mode (10 Hz, 60% duty cycle; 60 ms ON and 40 ms OFF), with a 400 µm optical fiber and power settings of 3 and 4 W. Total energy delivered to the submental region ranged from 500 to 1400 J, while epidermal temperature was maintained below 40 °C. Photographic assessments were performed at baseline and 30, 60, and 90 days after treatment. Submental area was measured using ImageJ® software, and statistical analyses were performed using IBM SPSS® version 24.0. At 90 days, the mean submental area decreased from 21.61 ± 6.58 cm² to 15.84 ± 6.15 cm², corresponding to a mean individual percentage reduction of 27.18 ± 13.89% ($p < 0.001$). Nine participants (90%) reported being very satisfied with the results. One transient case of marginal mandibular nerve neuropraxia was reported, with complete recovery within 40 days. These preliminary findings suggest that endolaser may improve submental contour and skin laxity. However, the small sample size, absence of a control group, short follow-up period, and reported adverse event warrant cautious interpretation and further controlled studies.

[1] Physiotherapist, graduated from the Federal University of Triângulo Mineiro (UFTM), Uberaba, Minas Gerais, Brazil.
[2] Dentist, MSc and PhD in Health Sciences from the Federal University of Triângulo Mineiro (UFTM). Postdoctoral researcher in Health Sciences, working in Hematology and Hemotherapy at UFTM, Uberaba, Minas Gerais, Brazil.
[3] Physician and Plastic Surgeon, MSc and PhD in Abdominal Surgery from the Federal University of Minas Gerais (UFMG). Associate Professor of Plastic Surgery at the Federal University of Triângulo Mineiro (UFTM), Uberaba, Minas Gerais, Brazil.
[4] MSc in Orofacial Harmonization from the European Face Institute, Porto, Portugal. Instructor at Mend Master Cursos em Saúde, Ribeirão Preto, São Paulo, Brazil.
[5] Physiotherapist, Specialist in Dermatofunctional Physiotherapy. Instructor at Mend Master Cursos em Saúde, Ribeirão Preto, São Paulo, Brazil.
[6] Physiotherapist, MSc in General Pathology and PhD in Health Sciences from the Federal University of Triângulo Mineiro (UFTM). Specialist in Dermatofunctional Physiotherapy and researcher in the field of Physiotherapy, Uberaba, Minas Gerais, Brazil.
[7] MSc in Biotechnology, with an emphasis on Regenerative Medicine, from the University of Araraquara (UNIARA). Professor at Faculdade Metropolitana do Estado de São Paulo (FAMEESP), Brazil.
[8] Physiotherapist, MSc in Bioengineering and PhD in Medical Sciences from the University of São Paulo (USP), Ribeirão Preto, Brazil. Completed postdoctoral research at USP. Full Professor at the Department of Applied Physiotherapy, Institute of Health Sciences, Federal University of Triângulo Mineiro (UFTM), Uberaba, Minas Gerais, Brazil.

This article is published in open access under the Creative Commons Attribution 4.0 International (CC BY 4.0) license, which permits unrestricted use, distribution, and reproduction in any medium, provided that the original author and source are credited.

SCIENTIFIC JOURNAL - RECIMA21 ISSN 2675-6218

KEYWORDS: *Chin. Face. Laser therapy. Optical fibers. Skin.*

RESUMO
O rejuvenescimento facial tem sido tradicionalmente realizado por meio de procedimentos cirúrgicos invasivos. O endolaser é uma técnica minimamente invasiva que pode melhorar a flacidez cutânea por meio da remodelação do tecido conjuntivo e da estimulação da síntese de colágeno. Este estudo teve como objetivo avaliar os efeitos do endolaser sobre a flacidez cutânea do terço inferior da face, região submentoniana e pescoço, bem como investigar associações entre os resultados do tratamento e a idade dos participantes. Trata-se de um estudo longitudinal, quase-experimental, do tipo série de casos, com dez voluntários (idade média de 50,7 ± 7,21 anos) e avaliadores cegados. Os participantes foram submetidos a uma única sessão com laser de diodo Delight® de 1470 nm, em modo pulsado (10 Hz, ciclo de trabalho de 60%; 60 ms ligado e 40 ms desligado), utilizando fibra óptica de 400 µm e potências de 3 e 4 W. A energia total aplicada na região submentoniana variou de 500 a 1400 J, enquanto a temperatura epidérmica foi mantida abaixo de 40 °C. Foram realizadas avaliações fotográficas antes do tratamento e aos 30, 60 e 90 dias após o procedimento. A área submentoniana foi mensurada por meio do software ImageJ®, e as análises estatísticas foram realizadas no IBM SPSS® versão 24.0. Aos 90 dias, a área submentoniana média diminuiu de 21,61 ± 6,58 cm² para 15,84 ± 6,15 cm², correspondendo a uma redução percentual média individual de 27,18 ± 13,89% ($p < 0,001$). Nove participantes (90%) relataram estar muito satisfeitos com os resultados. Foi registrado um caso transitório de neuropraxia do nervo marginal mandibular, com recuperação completa em 40 dias. Esses achados preliminares sugerem que o endolaser pode melhorar o contorno submentoniano e a flacidez cutânea. Entretanto, o tamanho reduzido da amostra, a ausência de grupo controle, o curto período de acompanhamento e o evento adverso relatado exigem uma interpretação cautelosa dos resultados e a realização de novos estudos controlados.

PALAVRAS-CHAVE: Face. Laserterapia. Pele. Fibras ópticas. Queixo.

RESUMEN
El rejuvenecimiento facial se ha basado tradicionalmente en procedimientos quirúrgicos invasivos. El endoláser es una técnica mínimamente invasiva que puede mejorar la flacidez cutánea mediante la remodelación del tejido conectivo y la estimulación de la síntesis de colágeno. Este estudio tuvo como objetivo evaluar los efectos del endoláser sobre la flacidez cutánea del tercio inferior del rostro, la región submentoniana y el cuello, así como investigar las asociaciones entre los resultados del tratamiento y la edad de los participantes. Se realizó un estudio longitudinal, cuasiexperimental, de serie de casos, con diez voluntarios (edad media: 50,7 ± 7,21 años) y evaluadores cegados. Los participantes recibieron una única sesión con un láser de diodo Delight® de 1470 nm en modo pulsado (10 Hz, ciclo de trabajo del 60 %; 60 ms encendido y 40 ms apagado), utilizando una fibra óptica de 400 µm y potencias de 3 y 4 W. La energía total aplicada en la región submentoniana osciló entre 500 y 1400 J, mientras que la temperatura epidérmica se mantuvo por debajo de 40 °C. Se realizaron evaluaciones fotográficas antes del tratamiento y a los 30, 60 y 90 días posteriores. El área submentoniana se midió mediante el software ImageJ®, y los análisis estadísticos se realizaron con IBM SPSS® versión 24.0. A los 90 días, el área submentoniana media disminuyó de 21,61 ± 6,58 cm² a 15,84 ± 6,15 cm², lo que correspondió a una reducción porcentual individual media del 27,18 ± 13,89 % ($p < 0,001$). Nueve participantes (90 %) manifestaron estar muy satisfechos con los resultados. Se registró un caso transitorio de neuropraxia del nervio marginal mandibular, con recuperación completa en 40 días. Estos hallazgos preliminares sugieren que el endoláser puede mejorar el contorno submentoniano y la flacidez cutánea. Sin embargo, el pequeño tamaño de la muestra,

This article is published in open access under the Creative Commons Attribution 4.0 International (CC BY 4.0) license, which permits unrestricted use, distribution, and reproduction in any medium, provided that the original author and source are credited.

la ausencia de un grupo de control, el corto período de seguimiento y el evento adverso registrado requieren una interpretación cautelosa y la realización de nuevos estudios controlados.

***PALABRAS CLAVE**: Fibras ópticas. Piel. Mentón. Rostro. Terapia láser.*

1. INTRODUCTION

In recent years, the search for minimally invasive aesthetic treatments has grown significantly, due to their effectiveness and rapid recovery when compared to traditional surgical procedures[1]. The deep and superficial midfacial fat compartments are located in the midface and this area is prone to age-related changes as the underlying bone undergoes remodeling, with a corresponding change in the maxillary angle. With age-related facial changes, the platysma muscle and the overlying (subcutaneous) fat compartment of the jowl slide inferiorly, causing the appearance of the jowls[2].

Therefore, sagging in the lower third of the face and neck refers to the loss of elasticity and firmness of the skin located in the submental region, and can be triggered by genetic factors, aging, excessive weight gain and lack of muscle tone in the neck region, characteristics that can impact the self-esteem and quality of life of individuals[3].

In the past, the concept of facial rejuvenation was dominated by invasive surgical procedures in different partial and full-face lifting techniques. Currently, there is a clear trend toward less invasive, faster, and simpler procedures that do not require patients to miss their routine and daily activities for prolonged periods. Several techniques have been developed to treat this condition, among which endolaser stands out[4].

Endolaser, in the Endolift® technique, is a minimally invasive procedure that consists of using a diode laser beam with a wavelength of 1470 nm emitted through an optical fiber, which is inserted into subcutaneous (juxtadermal) tissue promoting connective tissue remodeling and stimulating new collagen production. The mechanism of action consists of the insertion of a fiber directly into the superficial and medium hypodermis, whose positioning is identifiable due to a Light Emitting Diode (LED) that is visible through the skin. The fiber is moved throughout the intervention area in a similar pattern to a fan (vectors) and the laser energy is selectively absorbed by chromophores, leading to protein denaturation and stimulation of collagen synthesis by fibroblasts. In adipocytes, this denaturation alters metabolism, favoring the reduction of adipose tissue[5].

This technique is effective for treating sagging in the lower third of the face/neck and for reducing localized adiposity in the “double chin” region, with minimal discomfort and good

This article is published in open access under the Creative Commons Attribution 4.0 International (CC BY 4.0) license, which permits unrestricted use, distribution, and reproduction in any medium, provided that the original author and source are credited.

acceptance by volunteers[6]. The aim of this study is to evaluate the effects of endolaser, using the Endolift® technique, on sagging in the lower third of the face, submental region and neck and to correlate the results with the age of the volunteers.

2. MATERIAL AND METHODS

2.1. Study type

This was a clinical, quasi-experimental, longitudinal case series study with blinded evaluators, approved by the Research Ethics Committee of UFTM (CEP-UFTM; protocol number 6.332.806) and conducted at the Rehabilitation Center of the Clinical Hospital of the Federal University of Triângulo Mineiro, Uberaba, Minas Gerais, Brazil.

2.2. Study volunteers

Ten volunteers (nine women and one man), with a mean age of 50.7 ± 7.21 years, were included in this study. Participants presented skin laxity in the lower third of the face, submental region, and/or neck and were recruited through convenience sampling.

2.3. Procedures

Each volunteer received a single endolaser session using the Endolift® technique, performed with the Delight® 1470 nm device, pulsed mode, 10 Hz, 60% (60 ms ON and 40 ms OFF), 400 µm fiber, with a power of 3 W in the superficial hypodermis for sagging and 4 W in the middle hypodermis for adiposity in the submental region, with the dose adjusted so that the temperature did not exceed 40 °C in the epidermis. All volunteers received this application in the submental region; however, some also received the application in the lower third of the face or the neck region, according to need. The endpoint for each participant ranged from 500 J to 1400 J of total energy deposited in the submental region. For the neck, the average was 300–500 J on each side, and for the lower third of the face, it was 500–800 J. The region was previously anesthetized with 2% lidocaine with vasoconstrictor, diluted in saline solution (1:4).

After cleaning the area, the vectors were drawn, and anesthesia was applied to the superficial hypodermis with a 22 G cannula. Then, the optical fiber was inserted, and laser energy was delivered using a retrograde technique during the final three passes along each vector[7]. The temperature was monitored with a thermographic camera throughout the application. At the end, ice was applied for 20 minutes, and the tape was kept in place for five days (Fig. 1). Volunteers were instructed to continue applying ice for the first 48 hours and to use a chin brace to control

This article is published in open access under the Creative Commons Attribution 4.0 International (CC BY 4.0) license, which permits unrestricted use, distribution, and reproduction in any medium, provided that the original author and source are credited.

edema and inflammation. The entire procedure was performed using sterile equipment and following biosafety regulations.

Fig. 1. Marking of the vectors in the submental region (a), application of the anesthetic (b), application of the endolaser (c) and application of the post-procedure taping (d)



2.4. Photographic record

The photos were taken using an iPhone 14® cell phone camera (12-megapixel camera, with 3x optical zoom and 15x digital zoom, Apple®, California, USA), with standardized lighting and distance, with a blue nonwoven fabric (TNT) background, and a tape measure attached. The recordings were made in the frontal and lateral planes on both sides, respecting the Frankfurt plane, before the procedure and after 30, 60 and 90 days.

2.5. Clinical improvement

The photos were analyzed by two independent evaluators specializing in dermatofunctional physiotherapy, who measured the clinical improvement of the participants before and after 90 days. Clinical improvement was graded as 0 = no improvement,

This article is published in open access under the Creative Commons Attribution 4.0 International (CC BY 4.0) license, which permits unrestricted use, distribution, and reproduction in any medium, provided that the original author and source are credited.

1 = improvement up to 25%, 2 = improvement between 26 and 50%, 3 = improvement between 51 and 75%, and 4 = improvement between 76 and 100%[8].

2.6. Morphometric evaluation

The photographic images were quantitatively analyzed using ImageJ® software (version 1.54k), a freely available image analysis tool previously employed for morphometric measurements in facial studies, including assessments following endolaser treatment[9]. Quantitative assessment of the submental region using calibrated photographs has also been described by Mordon et al.[10], who estimated changes in submental fat volume following laser lipolysis. However, unlike their volumetric approach, the present study measured the two-dimensional submental area, expressed in cm².

After importing each photograph into ImageJ®, the software was calibrated using the tape measure as a reference. The submental area was then manually outlined with the mouse on lateral photographs, taking the mandibular angle, the contour of the mandibular ramus, and the skin contour beneath the chin as anatomical references. The resulting measurements were recorded in an Excel spreadsheet for comparison between baseline and 90 days after treatment (Fig. 2).

Fig. 2. The image shows the contour of the chin made by the ImageJ® Software to measure and compare the area before (a) and after (b) 90 days of the procedure in one of the volunteers



This article is published in open access under the Creative Commons Attribution 4.0 International (CC BY 4.0) license, which permits unrestricted use, distribution, and reproduction in any medium, provided that the original author and source are credited.

2.7. Pain assessment

To measure pain during the procedure, the Visual Analogue Scale (VAS) was used, which consists of a 10 cm line with extremes marked by the phrases “absence of pain” (represented by 0) and “unbearable pain” (represented by 10). This assessment was conducted during the application process and in subsequent weeks.

2.8. Satisfaction level

The assessment of the level of satisfaction perceived by the volunteers was carried out through a questionnaire and with the volunteers viewing their photographs taken before and 90 days after the procedure, and was graded as: a) dissatisfied; b) slightly satisfied; c) satisfied; d) very satisfied[8].

2.9. Statistical analysis

Data were analyzed using IBM SPSS Statistics® version 24.0. Continuous variables were expressed as mean ± standard deviation, and categorical variables as frequencies and percentages. The normality of paired differences was assessed using the Shapiro–Wilk test. Pre- and post-treatment submental areas were compared using the paired Student's t-test. Spearman's rank correlation coefficient was used to investigate associations between age and morphometric variables. Statistical significance was set at $p < 0.05$.

3. RESULTS

3.1. Clinical improvement

After 90 days of the procedure, a reduction in the double chin and an improvement in sagging in the lower third of the face and neck were observed. The skin in these regions showed visible retraction and improved appearance (Fig. 3 and Fig. 4). Improvements in skin texture, color, and luster were also reported by the volunteers, as illustrated in Fig. 4.

The evaluators graded the clinical improvement between 3 and 4, that is, from 51 to 100%, according to the Hodeib classification[8], which is considered a very significant improvement.

This article is published in open access under the Creative Commons Attribution 4.0 International (CC BY 4.0) license, which permits unrestricted use, distribution, and reproduction in any medium, provided that the original author and source are credited.

Fig. 3. Pre-procedure frontal view (a, c, e, and g) and frontal view 90 days after endolaser (b, d, f, and h); pre-procedure lateral view (i, k, m, and o) and lateral view 90 days after endolaser (j, l, n, and p), demonstrating skin retraction and double chin reduction



This article is published in open access under the Creative Commons Attribution 4.0 International (CC BY 4.0) license, which permits unrestricted use, distribution, and reproduction in any medium, provided that the original author and source are credited.

Fig. 4. Pre-procedure (a and c) and 90 days after endolaser (b and d) of one of the volunteers, demonstrating improvement in sagging and skin quality



3.2. Morphometric evaluation of submental area

Morphometric analysis demonstrated a statistically significant reduction in the submental area 90 days after endolaser treatment (Table 1, Fig. 5). The mean area decreased from 21.61 ± 6.58 cm² before treatment to 15.84 ± 6.15 cm² after treatment, corresponding to a mean absolute reduction of 5.77 ± 3.24 cm² and a mean individual percentage reduction of 27.18 ± 13.89%.

The paired Student's t-test demonstrated a statistically significant difference between pre- and post-treatment measurements ($t(9) = 5.641$; $p < 0.001$), with a 95% confidence interval for the mean absolute reduction ranging from 3.46 to 8.09 cm².

Spearman's correlation analysis revealed no statistically significant associations between age and baseline submental area ($\rho = 0.215$; $p = 0.551$), post-treatment area ($\rho = 0.190$; $p = 0.599$), absolute area reduction ($\rho = -0.006$; $p = 0.987$), or percentage area reduction ($\rho = -0.178$; $p = 0.623$).

This article is published in open access under the Creative Commons Attribution 4.0 International (CC BY 4.0) license, which permits unrestricted use, distribution, and reproduction in any medium, provided that the original author and source are credited.

Table 1. Age of participants, submental area before and 90 days after endolaser treatment, and absolute and percentage area reductions. Values are expressed as mean ± standard deviation. Statistical analysis: paired Student's t-test for pre- versus post-treatment submental area ($p < 0.001$)

Volunteer	Age	Area before (cm^2)	Area after (cm^2)	Reduction of the area (cm^2)	Reduction of the area (%)
1	60	17.871	15.736	2.135	11.95
2	47	23.977	20.400	3.577	14.92
3	55	29.978	25.904	4.074	13.59
4	47	10.975	8.715	2.260	20.59
5	38	26.105	21.694	4.411	16.90
6	63	29.855	20.431	9.424	31.57
7	48	22.027	14.376	7.651	34.73
8	52	23.443	13.979	9.464	40.37
9	50	11.989	8.051	3.938	32.85
10	47	19.889	9.085	10.804	54.32
Mean		21.611	15.837	5.774	27.18
Standard deviation		6.582	6.147	3.237	13.89

This article is published in open access under the Creative Commons Attribution 4.0 International (CC BY 4.0) license, which permits unrestricted use, distribution, and reproduction in any medium, provided that the original author and source are credited.

Fig. 5. The image shows the comparative graph of the average area (in cm²) of the submental region before the procedure and 90 days after the endolaser procedure

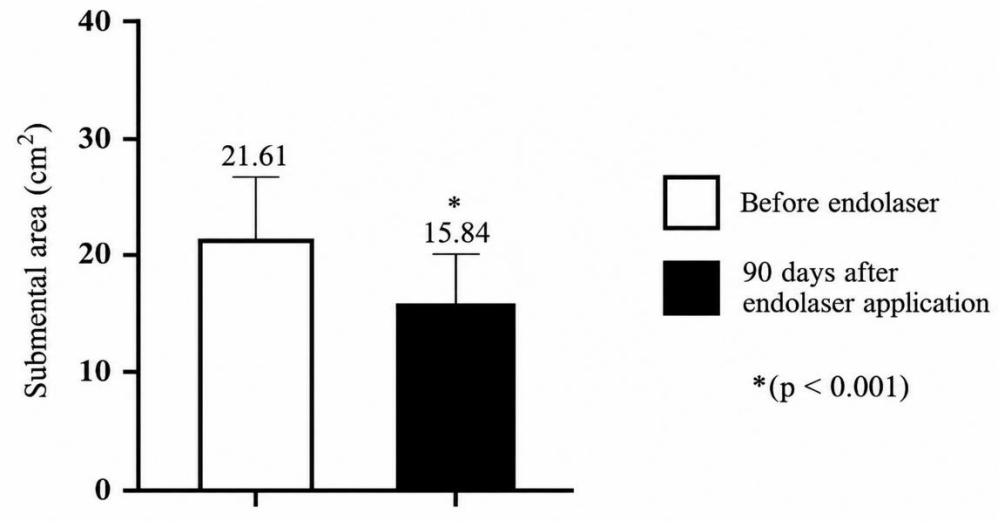

3.3. Pain level and satisfaction

During the procedure, due to the anesthesia, the volunteers did not report any pain or discomfort. During the subsequent weeks, there were also no reports of pain; VAS remained at 0. However, after the procedures, some volunteers reported discomfort related to edema or occasional ecchymosis. Volunteers were instructed to undergo physical therapy after the procedure to help reduce edema and prevent fibrosis. No fibrosis was observed at the 90-day reassessment. Volunteers reported being very satisfied with the results in 90% of cases, with only one volunteer (10%) reporting being slightly satisfied.

4. DISCUSSION

The clinical and morphometric results of this study demonstrated a significant reduction in the submental area and an improvement in sagging in the lower third of the face and neck, as well as improved skin texture. These findings may be associated with the thermal effects of endolaser, which can promote collagen remodeling and adipose tissue reduction. However, these mechanisms were not directly investigated in the present study. Although this study primarily focused on skin laxity, endolaser is also indicated for adipose tissue reduction, which may have contributed to the observed reduction in the submental area in some volunteers.

This article is published in open access under the Creative Commons Attribution 4.0 International (CC BY 4.0) license, which permits unrestricted use, distribution, and reproduction in any medium, provided that the original author and source are credited.

In areas with larger amounts of adipose tissue, the procedure appeared to be less effective in reducing submental volume. One volunteer, who reported being slightly satisfied with the results (Fig. 3a and Fig. 3b), showed a limited reduction in the submental area, although the mandibular contour improved due to apparent skin retraction. One possible explanation is the presence of deeper (post-platysmal) adipose tissue, although this was not confirmed by imaging examinations. Therefore, knowledge of the anatomy of the submental region is important to establish realistic treatment expectations. In the submental region, adipose tissue may be located superficial to the platysma (pre-platysmal fat), between the skin and the muscle, or deep to the platysma (post-platysmal fat), near the digastric muscles. Both compartments may contribute to submental fullness[11].

The mechanism of action of endolaser involves photothermal effects on adipose tissue and collagen-rich connective tissue in the treated region. Heat generated by laser irradiation may promote adipose tissue reduction and collagen denaturation, potentially contributing to collagen remodeling, increased skin firmness, and retraction[12]. Other studies have also reported improvements in skin laxity following endolaser treatment. However, heat-induced tissue shrinkage depends on several factors, including the maximum temperature reached, duration of heat exposure, and tissue hydration[13]. These mechanisms were not directly evaluated in the present study.

A single endolaser application was performed in this study using the Endolift® technique, with the following parameters: 1470 nm, pulsed mode, 10 Hz, 60% (60 ms ON and 40 ms OFF), 400 µm fiber, with insertion in the superficial hypodermis for sagging (with 3 W power) and insertion in the middle hypodermis for fat (with 4 W power), with the dose adjusted so that the temperature did not exceed 40 °C in the epidermis and the end point of each volunteer. The total energy deposited varied from 500 J to 1400 J in the submental region, similar to that described by Longo *et al.*[5] who also performed it in the lower third of the face with the same parameters. In this study, for the lower third of the face in volunteers who had this indication, the energy deposited was lower than that described by Longo *et al.*[5], not exceeding 800 J.

The parameters reported in the literature are not always clearly described and may occasionally contain inconsistencies. For example, Nilforoushzadeh et al.[4,14] reported power settings of 75–150 W, although the equipment described in those studies has a maximum output power of 15 W. In a subsequent publication, Nilforoushzadeh et al.[15] reported power settings of 3.5–4 W, which are consistent with the power settings used in the present study. It is also not uncommon to find studies that do not report the power settings employed[5,16,17]. Overall, the power settings used in the present study are consistent with those described by other authors[3,5,9,18].

This article is published in open access under the Creative Commons Attribution 4.0 International (CC BY 4.0) license, which permits unrestricted use, distribution, and reproduction in any medium, provided that the original author and source are credited.

Other laser parameters are not consistently reported in the literature, which limits the standardization of effective and safe endolaser protocols. Regarding pulsed laser emission, Benar et al.[1] and Nilforoushzadeh et al.[17] described a duty cycle of 50%, corresponding to 50 ms ON and 50 ms OFF, whereas Wilde et al.[19] and Dell'Avanzato[20] reported a duty cycle of 25%, corresponding to 25 ms ON and 75 ms OFF. Both configurations correspond to a frequency of 10 Hz, calculated by dividing 1000 ms by the total duration of each pulse cycle (ON time + OFF time). In the present study, pulsed emission was also performed at 10 Hz, but with a 60% duty cycle (60 ms ON and 40 ms OFF). Other studies have reported continuous laser emission with higher power settings for facial treatments. For example, Dias et al.[21] used continuous emission at 4–8 W for submental fat reduction. However, these parameters differ from the pulsed emission protocols described above.

Regarding the total energy delivered, Longo et al.[5] described doses ranging from 500 to 1400 J for the submental region, with an average of approximately 800 J, depending on the treatment endpoint. The endpoint was described as the point at which skin retraction becomes apparent and increased resistance to fiber movement is observed. Nilforoushzadeh et al.[4] and Saran et al.[18] reported using between 600 and 800 J in the submental region, with favorable clinical outcomes. In the present study, total energy ranged from 500 to 1400 J in the submental region, consistent with the range described by Longo et al.[5]. For participants who also underwent treatment of the lower third of the face, total energy did not exceed 800 J. In the neck region, energy delivery did not exceed 500 J per side, a range also described by Nilforoushzadeh et al.[22].

Wavelength is another parameter that should be discussed, because although the Endolift® technique makes it clear that it uses only the 1470 nm wavelength, where the target chromophore is water, some professionals, especially in Brazil, ended up relying on articles that used other wavelengths, such as those for laser lipolysis[16,23,24]. However, the parameters for 1470 nm should be completely different, since its thermal confinement is high and does not quickly and significantly raise the temperature of the epidermis. Thus, many endolaser injuries have occurred in Brazil, as professionals used parameters from other wavelengths for the 1470 nm wavelength[25]. In view of this, we suggest carefully reading the article by Youn *et al.*[26] on thermal confinement at different wavelengths, and it is recommended that applications of the technique have at least a basis in the available scientific literature.

Regarding temperature control, the photothermal effects of laser-assisted procedures depend on several factors, including wavelength, power, energy delivery, tissue optical properties, and exposure time. Mathematical modeling of laser lipolysis has demonstrated the importance of heat distribution within tissues; however, findings obtained with wavelengths of 980

This article is published in open access under the Creative Commons Attribution 4.0 International (CC BY 4.0) license, which permits unrestricted use, distribution, and reproduction in any medium, provided that the original author and source are credited.

and 1064 nm cannot be directly extrapolated to the 1470 nm diode laser used in the present study[10]. Differences in wavelength and tissue absorption characteristics may influence the thermal response and the risk of adverse events[26,27]. Therefore, careful temperature monitoring is essential during endolaser procedures, particularly because epidermal temperature does not necessarily reflect the temperature reached in deeper tissues. In the present study, epidermal temperature was monitored using a thermographic camera and maintained below 40 °C. When this threshold was reached, laser emission was interrupted, and the treated area was cooled. This temperature limit was adopted as a precautionary measure in the present protocol and should not be interpreted as a universally established safety threshold for 1470 nm endolaser procedures.

The variables evaluated in this study suggest that the Endolift® technique may be effective in reducing the submental area. All volunteers underwent endolaser treatment in the submental region; therefore, morphometric measurements were performed in this area using ImageJ® software. However, few studies have performed or described morphometric evaluations. In the study by Lotfi et al.[9], the authors also used ImageJ® to perform morphometric measurements, but in the periorbital region, whereas Nilforoushzadeh et al.[4] used VisioFace®, and Wilde et al.[19] used VECTRA® software. In the present study, ImageJ® was chosen because it is a free, easily accessible tool that facilitates the reproducibility of the measurement procedure. Nevertheless, measurements based on two-dimensional photographs may be influenced by variations in head positioning, camera angle, and anatomical landmark identification. For future studies, it is suggested that standardized anatomical reference points be marked during photographic documentation to improve the accuracy of area delimitation.

Regarding satisfaction, 90% of volunteers reported being very satisfied with the results 90 days after the procedure. Most articles do not mention the volunteers' satisfaction level, and although the images demonstrate clinical improvement, it is difficult to determine whether the treatment met the volunteers' expectations. Therefore, it is difficult to establish a correlation between the results of this study and those found in the literature regarding satisfaction levels.

Clinical improvement was observed and classified as grade 3 or 4, corresponding to 51% to 100% improvement, according to the assessments of two independent and experienced evaluators. This assessment was also not cited in other studies; most studies report only clinical improvement based on the authors' perception, without grading it. Although not measured, other studies have shown similar results in terms of clinical improvement[18,19]. In this study, no statistically significant correlation was identified between the age of the volunteers and the evaluated outcomes. However, given the small sample size, this finding should not be interpreted as evidence that age does not influence treatment response. It is biologically plausible that

This article is published in open access under the Creative Commons Attribution 4.0 International (CC BY 4.0) license, which permits unrestricted use, distribution, and reproduction in any medium, provided that the original author and source are credited.

younger individuals may exhibit a greater response to collagen remodeling therapies, considering that age-related changes in fibroblast function and extracellular matrix organization have been associated with reduced collagen synthesis in aged skin[28]. Nevertheless, further studies with larger samples are needed to investigate the potential influence of age on endolaser treatment outcomes.

Regarding pain, few authors describe or measure this variable. In the present study, no pain was reported during the procedure or in the subsequent days and weeks; only mild discomfort associated with edema and ecchymosis was observed. These findings are consistent with studies reporting transient post-treatment edema and mild erythema[4,5,21,29].

In this study, the medical team prescribed dexamethasone 4 mg for the first three days and prophylactic antibiotics for seven days. The necessity of routine antibiotic prophylaxis in endolaser procedures remains uncertain and requires further investigation. Edema and ecchymosis were also observed after treatment. These events were managed with taping, lymphatic drainage, ice application, and photobiomodulation therapy.

This study reported a transient adverse event involving neuropraxia of the marginal mandibular nerve in one volunteer. This volunteer had undergone facial PDO thread placement six months before the endolaser procedure. However, no causal relationship between the previous procedure and the occurrence of neuropraxia could be established. The patient received Etna®, laser therapy, and electrical stimulation, with complete resolution of the neurological symptoms within 40 days. Although the underlying mechanism of this adverse event remains uncertain, this finding highlights the importance of careful anatomical assessment, appropriate treatment parameters, and monitoring for potential neurological complications during endolaser procedures. Potential complications associated with endolaser procedures have also been discussed in the literature[25].

Studies have shown that the 1470 nm diode laser has demonstrated promising results in endolaser procedures and is commonly used without liposuction, that is, using only optical fibers. Thus, the technique may represent a less invasive alternative for reducing subcutaneous tissue and improving skin firmness[18,30]. The findings of the present study are consistent with reports of clinical improvement following endolaser treatment; however, its safety profile requires further investigation in larger, controlled studies. Regarding fat reduction, expectations must be aligned with the actual effects of endolaser, since this reduction is generally less pronounced than that achieved with liposuction. An important limitation is the limited availability of high-quality scientific evidence on endolaser procedures, particularly studies with robust methodological designs and standardized treatment protocols. These gaps in the literature make it difficult to establish

This article is published in open access under the Creative Commons Attribution 4.0 International (CC BY 4.0) license, which permits unrestricted use, distribution, and reproduction in any medium, provided that the original author and source are credited.

evidence-based recommendations regarding treatment parameters, efficacy, and safety. Such limitations are also discussed in the scoping review by Vidal et al.[29].

The high cost of therapy can also be considered a limitation, given the expenses associated with equipment and consumables. This study was funded by the researchers, which limited the number of volunteers and the number of treatment sessions. Different treatment approaches and parameters have been described in the endolaser literature[5,22]. However, the optimal number of sessions and intervals between treatments remain uncertain. In the present study, only one endolaser session was performed, with clinically relevant results. Therefore, further studies are needed to determine whether additional sessions could provide greater or more sustained improvements.

5. FINAL CONSIDERATIONS

The findings of this study suggest that endolaser, using the Endolift® technique and the parameters employed, may improve skin laxity in the lower third of the face, submental region, and neck, with a statistically significant reduction in the submental area. No statistically significant correlation was observed between age and treatment outcomes; however, the small sample size limits the interpretation of this finding. Although clinical improvement and high patient satisfaction were observed, the occurrence of a transient neuropraxia highlights the need for careful consideration of potential adverse events. Further studies with larger samples, control groups, and longer follow-up periods are needed to confirm the effectiveness and safety of this technique.

REFERENCES

1. H. Benar, E. B. Benar, “A new nonsurgical combination approach for skin tightening and remodeling; Endoskin–A comparative study”. *Journal of Cosmetic Dermatology* 23(8) (2024):2574–2580, https://doi.org/10.1111/jocd.16306 .

2. T. L. Schenck, K. C. Koban, A. Schlattau, K. Frank, J. Sykes, et al., “The functional anatomy of the superficial fat compartments of the face: a detailed imaging study”. *Plastic and Reconstructive Surgery* 141(6) (2018):1351–1359, https://doi.org/10.1097/PRS.0000000000004364

3. Y. Wakabayashi, J. L. Sobral, F. M. Rodrigues, J. R. Ferraz, “Perspectivas do Endolift com laser de diodo 1470 nm no tratamento da gordura submentoniana: uma análise bibliográfica,” *RECIMA21-Revista Científica Multidisciplinar* 5(9), (2024) e595689, https://doi.org/10.47820/recima21.v5i9.5689 .

This article is published in open access under the Creative Commons Attribution 4.0 International (CC BY 4.0) license, which permits unrestricted use, distribution, and reproduction in any medium, provided that the original author and source are credited.

4. M. A. Nilforoushzadeh, M. Heidari-Kharaji, T. Fakhim, A. Hanifnia, M. Nouri, et al., “Endolift laser for jowl fat reduction: clinical evaluation and biometric measurement,” *Lasers in Medical Science* 37(5) (2022):2397–2401, https://doi.org/10.1007/s10103-021-03494-9 .

5. L. Longo, R. Dell’Avanzato, D. Longo, “Endolift® and multi-wavelength laser photobiomodulation: a randomized controlled trial study on 96 subjects, treating skin laxity of the lower third of the face,” *Laser Therapy*, 29(1) (2022): 115–120. https://doi.org/10.4081/ltj.2022.298

6. M. A. Nilforoushzadeh, M. Heidari-Kharaji, T. Fakhim, S. T. Hosseini, S. Rafiee, et al., “Efficacy evaluation of endolift laser for treatment of nasolabial folds and marionette lines,” *Skin Research and Technology* 29(10) (2023):e13480, https://doi.org/10.1111/srt.13480

7. L. Scrimali, G. Lomeo, “Endolaser soft lift: from theory to practice,” *Union of Aesthetic Medicine–UIME* (2015).

8. A. A. Hodeib, G. F. Hassan, M. N. Ragab, E. A. Hasby, “Clinical and immunohistochemical comparative study of the efficacy of carboxytherapy vs platelet-rich plasma in treatment of stretch marks,” *Journal of Cosmetic Dermatology* (2018): https://doi.org/10.1111/jocd.12481

9. E. Lotfi, R. Dell’Avanzato, N. Ahramiyanpour, F. Shadmanyazdi, S. Khosravi, “Evaluation of eyebrow position and upper eyelid laxity after endolift laser treatment,” *Skin Research and Technology* 29 (2023): e13498, https://doi.org/10.1111/srt.13498

10. S. R. Mordon, B. Wassmer, J. P. Reynaud, J. Zemmouri, “Mathematical modeling of laser lipolysis,” *BioMedical Engineering OnLine* 7 (2008): 10, https://doi.org/10.1186/1475-925X-7-10

11. S. Y. Park, S.-B. Kim, J. Wan, F. Felice, K.-H. Yi, “Lipolytic agents for submental fat reduction: Review,” *Skin Research and Technology* 30 (2024): e13601. https://doi.org/10.1111/srt.13601

12. L. Scrimali, G. Lomeo, R. Dell’Avanzato, A. Crippa, “Endolaser soft-lift: a new approach on body contouring. Perspective and suggestions,” *European Journal of Aesthetic Medicine and Dermatology*, 3(3) (2013): 86–90. Available at: https://alpmed.co/wp-content/uploads/2023/01/endoliftEJAMeD.pdf

13. A. Oliveira de Moura, F. S. Borges, A. C. Ramos de Moura, “Endolaser treatment of aesthetic disorders: clinical experience of 4 years,” *International Journal of Medical Science and Clinical Invention* 10(5)(2023):6770–6782, https://doi.org/10.18535/ijmsci/v10i5.011

14. M. A. Nilforoushzadeh, M. Heidari-Kharaji, T. Fakhim, N. N. Nobari, E. Torkamaniha, A. Hanifnia, E. Behrangi, “Endolift laser an effective method for the lower eye bag treatment: a case series study,” *Lasers in Medical Science*, 37(8)(2022):3123-3128, https://doi.org/10.1007/s10103-022-03571-7

15. M. A. Nilforoushzadeh, M. Heidari-Kharaji, et al., “Static glabellar lines treated with the Endolift laser (1470 nm diode laser): a case report,” *Skin Research and Technology* 30(4) (2024): e13664, https://doi.org/10.1111/srt.13664

This article is published in open access under the Creative Commons Attribution 4.0 International (CC BY 4.0) license, which permits unrestricted use, distribution, and reproduction in any medium, provided that the original author and source are credited.

16. S. Tagliolatto, O. G. Leite, “Laserlipolysis in the cervical region,” *Surgical & Cosmetic Dermatology* 7(2) (2015): 149–157. https://doi.org/10.5935/scd1984-8773.201572544

17. M. A. Nilforoushzadeh, M. Heidari-Kharaji, T. Fakhim, E. Behrangi, M. Shahverdi, et al, “Efficacy of Endolift laser for arm and under abdomen fat reduction,” *Journal of Cosmetic Dermatology*, 22(7)(2023):2018-2022, https://doi.org/10.1111/jocd.15684

18. C. G. R. Saran, L. M. R. Simão, R. D. F. Z. Lizarelli, “Liftlaser dual-wave-técnica empregando lasers de diodo cirúrgicos para harmonização orofacial,” *Aesthetic Orofacial Science* 4(3)(2023):46–57, https://doi.org/10.51670/aos.v4i3.180

19. C. Wilde, M. Kaushik, I. Neumann, P. Verma, E. A. Azzopardi, D. G. Ezra, “Safety and efficacy of subcutaneous diode laser as a novel treatment in the management of festoons,” *Lasers in Medical Science*, 38(1)(2023):170, https://doi.org/10.1007/s10103-023-03830-1

20. R. Dell’Avanzato, “Endolift®: the ‘lunch-time’ laser lifting for the lower eyelids,” *Laser Therapy*, 29(2)(2022), https://doi.org/10.4081/ltj.2022.307

21. L. Dias, A. Denise, F. S. Borges, C. Bravin, S. Cruz, et al, “1470 nm diode laser effectiveness in facial fat reduction with the endolifting technique: pilot study,” *International Journal of Medical Science and Clinical Invention* 10(6)(2023):6788–6795, https://doi.org/10.18535/ijmsci/v10i6.02

22. M. A. Nilforoushzadeh, M. Heidari-Kharaji, N. N. Nobari, E. Torkamaniha, S. Rafiee, M. Shahverdi, et al, “Treatment of horizontal neck wrinkles by Endolift laser: Biometric measurement,” *Skin Research and Technology*, 30(4) (2024):e13697, https://doi.org/10.1111/srt.13697

23. A. Goldman, D. E. Schavelzon, G. S. Blugerman, “Laserlipólise: lipoaspiração com Nd-YAG laser,” *Revista Brasileira de Cirurgia Plástica*, 17(1) (2002): 17–26. https://www.rbcp.org.br/details/257/pt-BR/laserlipolise--lipoaspiracao-com-nd-yag-laser

24. J. D. Holcomb, “Thermally confined micropulsed 1444-nm Nd:YAG interstitial fiber laser in the aging face and neck: an update,” Facial Plastic Surgery Clinics of North America, 22(2) (2014): 217–229. https://doi.org/10.1016/j.fsc.2014.01.005

25. F. S. Borges, R. S. Jahara, P. F. Meyer, A. C. T. de Almeida, M. Almeida, A. C. Mendonça, “Complications from laser Endolift use: Case series and literature review,” *World Journal of Biology Pharmacy and Health Sciences*, 16(3) (2023): 23–41. https://doi.org/10.30574/wjbphs.2023.16.3.0496

26. J. I. Youn, J. D. Holcomb, “Ablation efficiency and relative thermal confinement measurements using wavelengths 1,064, 1,320, and 1,444 nm for laser-assisted lipolysis,” *Lasers in Medical Science*, 28(2) (2013): 519–527. https://doi.org/10.1007/s10103-012-1100-9

27. F. S. Borges, G. M. A. Xavier, D. M. O. Assis, J. A. Santos, V. D. F. Simões, L. L. Santos, G. P. P. Vidal, “Importance of temperature control during the subdermal endolaser technique utilization,” *International Journal of Development Research*, 14(4) (2024): 65370–65375. https://doi.org/10.37118/ijdr.28146.04.2024

This article is published in open access under the Creative Commons Attribution 4.0 International (CC BY 4.0) license, which permits unrestricted use, distribution, and reproduction in any medium, provided that the original author and source are credited.

28. J. Varani, M. K. Dame, L. Rittie, S. E. G. Fligiel, S. Kang, G. J. Fisher, J. J. Voorhees, “Decreased collagen production in chronologically aged skin: roles of age-dependent alteration in fibroblast function and defective mechanical stimulation,” *The American Journal of Pathology* 168(6) (2006): 1861–1868, https://doi.org/10.2353/ajpath.2006.051302

29. G. P. Vidal, N. A. Parizotto, F. S. Borges, L. de Assis, C. R. Tim, A. L. M. de Andrade, “Scientific evidence on the impact of endolaser in aesthetics: scoping review,” *Lasers in Medical Science*, 40(1) (2025): 155. https://doi.org/10.1007/s10103-024-04248-z

30. S. S. D. Correia Júnior, A. K. C. G. da Silva, A. B. Souza, D. C. S. P. Nicácio, “Endolaser para rejuvenescimento facial: uma revisão narrativa,” *Research, Society and Development*, 12(14) (2023): e129121443711. https://doi.org/10.33448/rsd-v12i14.43711

This article is published in open access under the Creative Commons Attribution 4.0 International (CC BY 4.0) license, which permits unrestricted use, distribution, and reproduction in any medium, provided that the original author and source are credited.