RECIMA21 - REVISTA CIENTÍFICA MULTIDISCIPLINAR
ISSN 2675-6218

# CUTANEOUS AND CLINIC MANIFESTATIONS IN PATIENTS DIAGNOSED WITH COVID19 OF AMAZON: SERIAL CASE REPORT

# MANIFESTAÇÕES CUTÂNEAS E CLÍNICAS EM PACIENTES DIAGNOSTICADOS COM COVID-19 NA AMAZÔNIA: SÉRIE DE CASOS

# MANIFESTACIONES CUTÁNEAS Y CLÍNICAS EN PACIENTES DIAGNOSTICADOS CON COVID19 DE AMAZON: INFORME DE CASO EN SERIE

Thales Ricardo Melo de Souza[1], Polyana Nathércia Vale da Luz[2], Lorena Garcia da Fonseca[3], Lucas Motta Gadelha Silva[4], Mariana Norberto de Araújo[5], Karla Valéria Batista Lima[6], Ademir Ferreira da Silva Junior[7]

**Submitted em: 07/30/2021** e28635
**Approved em: 09/08/2021** https://doi.org/10.47820/recima21.v2i8.635

**ABSTRACT**
In 2019, a new obscured pneumonia was reported by Wuhan Chinese scientists. Posteriorly, SARS-Cov-2 structure was identified, furthermore the pathology caused by this virus was named as COVID-19. The period of incubation of this disease is something about 4 or 5 days before the onset of symptoms, with 97,5% of patients having 11,5 days of symptoms nearly. Furthermore, affected patients are having cutaneous manifestations, in addition to the classic pulmonary, laboratorial, and systemic affection. Thus, the goal of the present article was the description of the clinical, cutaneous and laboratorial manifestations in adults of 18 to 59 years old affected by COVID19 and supported by São Rafael hospital, localized in Altamira- Pará, a region of Amazon.

**KEYWORDS**: Rash. COVID-19. Dermatology. Epidemiology, SARS-Cov-2

**RESUMO**
Em 2019, uma nova pneumonia de origem obscura foi relatada por cientistas de Wuhan, China. Posteriormente, o SARS-Cov-2 foi identificado e a sua patologia denominada por COVID-19. O seu período médio de incubação é de aproximadamente 4 a 5 dias antes do início dos sintomas, com 97,5% de pacientes sintomáticos desenvolvendo sintomas com duração média de 11,5 dias. Além dos sintomas respiratórios e gripais, os pacientes afetados podem demonstrar alterações em exames laboratoriais comuns, exames de imagem e alterações dermatológicas. Dessa forma, o objetivo do presente estudo é descrever as manifestações clínicas e cutâneas relacionadas à infecção por COVID19 em adultos de 18 a 59 anos de idade atendidos no Hospital São Rafael, em Altamira no estado do Pará. Trata-se de um estudo descritivo do tipo série de casos, o qual será desenvolvido a partir da análise de prontuários de pacientes atendidos no Hospital São Rafael, diagnosticados com a COVID-19 e que apresentaram manifestações clínicas, laboratoriais e dermatológicas associadas à doença.

**PALAVRAS-CHAVE**: Rash. COVID-19. Dermatologia. Epidemiologia. SARS-Cov-2

[1] Interno do curso de medicina da instituição UEPA, monitor durante um ano do departamento de dermatologia DSES
[2] Interna do curso de medicina da instituição UEPA, monitor durante um ano do departamento de dermatologia DSES
[3] Acadêmica do curso de medicina da instituição UEPA
[4] Acadêmico do curso de medicina da instituição UEPA
[5] Interna do curso de medicina da instituição UEPA
[6] Farmacêutica, doutora em Genética e Biologia Molecular. Professor adjunto IV da Universidade do Estado do Pará. Foi coordenadora do Programa de Pós-graduação em Biologia Parasitaria na Amazônia/ UEPA e IEC
[7] Pós-doutor na área de Segurança do Paciente pelo Programa de Pós-graduação em Biologia Parasitária na Amazônia da Universidade do Estado do Pará e University of Dubai. Professor Adjunto da Universidade Federal do Pará

RECIMA21 - REVISTA CIENTÍFICA MULTIDISCIPLINAR
ISSN 2675-6218



**RESUMEN**
En 2019, científicos chinos de Wuhan informaron de una nueva neumonía oscurecida. Posteriormente, se identificó la estructura del SARS-Cov-2, además la patología causada por este virus fue denominada como COVID-19. El período de incubación de esta enfermedad es algo así como 4 o 5 días antes de la aparición de los síntomas, con un 97,5% de los pacientes que tienen casi 11,5 días de síntomas. Además, los pacientes afectados están teniendo manifestaciones cutáneas, además de la clásica afección pulmonar, de laboratorio y sistémica. Por lo tanto, el objetivo del presente artículo fue la descripción de las manifestaciones clínicas, cutáneas y de laboratorio en adultos de 18 a 59 años afectados por COVID19 y apoyados por el hospital São Rafael, localizado en Altamira-Pará, una región de la Amazonía.

**PALABRAS CLAVE**: Erupción. COVID-19. Dermatología. Epidemiología. SARS-Cov-2

## INTRODUCTION

The first cases of the new coronavirus started in December 2019, in Hubei province, precisely in a group of admitted patients with a diagnose of pneumonia without etiology, in hospitals of Wuhan city [1]. The COVID-19 is characterized by a clinical disease started by the infection of respiratory tract caused by the SARS-CoV-2 virus, who is an RNA betacoronavirus, belonging to *Nidovirales* order and *Coronaviridae* family [1,2,3,4].

In this scenery, clinical manifestations are variable, and the severity depends of the clinical factors of the patients. Something about 80% of them are classified like low cases, generally having fever, dry cough, and fatigue. In several cases, 5% of them, occur progressive dyspnoea, lung bleeding, severe lymphopenia e renal insufficiency. It is important to stand out when the patient presents dyspnoea, thoracic distress, saturation less than 95%, cyanosis, the clinical case are defined by Severe Acute Respiratory Syndrome [1,2,3,4].

About the diagnose aspects, they are realized by health professionals who must evaluate the presence of clinical criteria. About laboratorial exams, the gold standard is the Reverse-Transcriptase Polymerase Chain Reaction (RT-PCR) method, referent about the reaction of polymerase chain with reverse transcription, being reference for definitive diagnose in infections caused by the new coronavirus, usually associated with positive radiologic searches [2,4,5].

Similarly, studies reveal that SARS-CoV-2 can cause a systemic adversity in infected people, their consequences and symptoms are not limited in airways and lungs. Not only dyspnoea and fever, but also mental confusion, irritability, dizziness, troubles to walk, agitation, enteric and gastric disease, renal insufficiency and cutaneous manifestations some patients may presents [3,4,6,7,8].

In Concerning to the cutaneous manifestation caused by COVID-19, first posts showed that the new virus SARS-CoV-2 may cause erythematous rash, generalized urticarial and “chickenpox like lesions” in patients facing different phases of this disease [7]. There are described reports in the literature which shows that this virus caused alterations like, maculopapular rash and erythematous eruptions in children diagnosed with the COVID-19 [8]. According to this exposition, the present

RECIMA21 - REVISTA CIENTÍFICA MULTIDISCIPLINAR
ISSN 2675-6218



research will report a serial case about the cutaneous and clinic manifestations in patients diagnosed with COVID-19 who are living in some cities of Amazon.

## METHOD

This is a descriptive study in serial cases format, with qualitative approach. The data research was analysed in august of 2020, studying supported patients of São Rafael Hospital, localized in Altamira, a city of Amazon- Pará. The sample of this research was composed by patients diagnosed with COVID-19 having clinical and cutaneous manifestations in a period of march till June 2020. It was included adults of 18 until 59 years, who received COVID-19 diagnose by serological, fast test, RT-PCR, or computed tomography. It was excluded patients with age less than 18 years or more than 59 years, as well, patients with incomplete medical record and people who refused to sign the consent form. The data was gated directly in the medical records of the patients, where was reported information about laboratorial exams, radiological founds, and picture of cutaneous lesions, posteriorly these data was registered in a research form designed by the authors. We analyzed these variants: laboratorial changes, tomographic lesions, cutaneous lesions, pruritic, use of topical medicines, methods of diagnose like RT-PCR, TC, serological exam.

## DESCRIPTION OF THE CASES

Patient A

Patient living in Belém-PA, woman, 42 years, have not present comorbidities. Reported the emergence of urticarial pattern of lesions, starting on the both legs, going to the right arm and thumb, with intense itch. After some days reported the emergence of fever, dyspnoea in average efforts, headache, fatigue, myalgia, dysgeusia, olfaction disorder, and diarrhoea. The diagnose for COVID-19 was given for positive serology. Complementary exams: FPG - 95mg/dL. Blood Cell Count: RBC- 4,23 million/mm³; HGB- 13,7g/dL, HT- 40,1%; MCV- 94,8 fL, MCH- 32,4pg/cell, MCHC- 34,2%, RDW- 11,8% Hb/cell, Platelets- 189.000/mm. WBC- 4370 cells/mm³, neutrophil- 2360 cells/mm³, lymphocyte- 1879 cells/mm³, VHS- 23mm/h. Triglycerides- 445mg/dL; ALT- 60U/L; AST-48U/L; Total cholesterol- 113mg/dL; HDL- 54mg/dL; Used medicines: loratadine, substituted for Pseudoephedrine + fexofenadine, azithromycin, paracetamol and multivitamin.

Patient B

Woman living in Altamira-PA, 48 years, without comorbidities. Reported the emergence of sore throat, myalgia, arthralgia e fever, without dyspnoea. One day after, skin revels erythematous plaques with papules compatible with maculopapular rash and some purpuric pointed lesions, localized in trunk and legs. COVID-19 diagnose was made by serologic test with positive result. Complementary exams: Blood Cell Count: RBC- 4,22 million/mm³, HB- 12.5g/dL, HT- 37,2%, MCV- 88,2fL, WBC 4040 cells/mm³, neutrophil 1591 cells/mm³, platelets 136.000/mm³; Total bilirubin - 0,81mg/dL, DB-

RECIMA21 - REVISTA CIENTÍFICA MULTIDISCIPLINAR
ISSN 2675-6218



0,30mg/dL, IB- 0,51mg/dL; Creatinine- 0,75mg/dL, GGT 26,9U/L; AST 19,7U/L; ALT 14,9U/L. Didn't use medications.

Patient C

Patient living in Altamira-PA, Woman, 41 years, without comorbidities. Referred intense abdominal discomfort associated to nausea, one day after, fever and diarrhoea. After two days, reported cutaneous disease characterized by erythema in chirodactyl, compatible with pseudo-chilblain, also having high itch, without dyspnoea and another symptom. Physical examination: Peripheral oxygen saturation ($spO_2$)- 99%, HR 89 beats per minute (bpm), axillary temperature- 38,4ºC. COVID-19 diagnose was given by serologic exam -19. Complementary exams: FPG 120mg/dL. RBC- 4.49million/$mm^3$; HB 13,6g/dL, HT 41%, MCV 91,4fL, MCH 30,4pg/cell, MCHC 33,2%, RDW 12,8%; WBC: 10.800 cells/$mm^3$, neutrophil: 8532 cells/$mm^3$, Lymphocytes: 1620 cells/$mm^3$, platelets: 251.000/$mm^3$. ALP: 66U/L, AST 16U/L, ALT 25U/L, Total bilirubin 0,7mg/dL, DB 0,2mg/dL, IB 0,5mg/dL, GGT 23U/L. Used drugs: azithromycin, ivermectin, chloroquine**,** paracetamol, enoxaparin.

Patient D

Patient living in Altamira-PA city, woman, 33 years, without associated comorbidities. Referred headache, dry cough, and dyspnoea in average efforts. In the thirsty day of disease, she reported the emergence of erythematous punctate macule, compatible to maculopapular rash, less than 3 mm and low associated itch in abdomen area. In addition, this patient had erythema in the back of her hand, compatible to pseudo-chilblain. Diagnose was defined by the nasopharyngeal swab detectable for COVID-19. Physical exam: TAX: 37,8ºC and $spO_2$: 98%. Complementary exams: Thorax CT showed ground-glass opacities taking a pulmonary area less than 5%. She used only symptomatic drugs.

Patient E

Man living in Altamira- PA, 57 years, having this comorbidity: hypertension, Diabetes Mellitus 2, obesity. Patient referred coryza, myalgia, headache and chills, without dyspnoea and another symptom. After 4 weeks of the onset of these symptoms, referred the emergence of cutaneous erythematous lesions with itch localized in pododactyls, also compatible to pseudo-chilblain. Diagnosed by serology using immunofluorescence with immunoglobulin M (IgM) and immunoglobulin G (IgG) positives for SARS-CoV-2. Used drugs: only symptomatic drugs for the present disease, for the comorbidities: losartan and metformin.

Patient F

Patient living in Altamira-PA, man, 30 years, without associated comorbidities. Reported compatible symptoms to sinusitis: nasal congestion and pain in sinuses, one day after he had dysgeusia e anosmia and reported fever, with progressive worsening of the facial pain and fever in the thirty days of symptoms. From the thirty to fourteenth day of disease referred arthralgia, myalgia, fatigue and headache, continuing with sinuses pain. After the onset of these flu symptomatology, urticarial lesions with intense itch appears with full body dissemination. Diagnosed for COVID-19 made with serological

RECIMA21 - REVISTA CIENTÍFICA MULTIDISCIPLINAR
ISSN 2675-6218



exam. Complementary exams: Thorax CT realized after 7 days of disease, without lesions. Used drugs: symptomatic drugs and azithromycin, hydroxychloroquine and prednisone.

Patient G

Woman living in Altamira-PA, 37 years, without associated comorbidities. Patient reported dry caught and fever for two days, also thoracic pain and fatigue. After these typical flu symptoms, skin shows urticarial disseminated lesions with intense itch, she also reported dysgeusia and anosmia. Diagnosed by fast COVID-19 test. Complementary exams: thorax CT showing ground-glass opacities taking less than 5% of lungs tissue. Used medicines: only paracetamol.

Patient H

Man living in Altamira-PA, 36 years, without comorbidities. Having a reported case with headache, fever, myalgia, caught, breath discomfort and diarrhoea which stopped after 10 days of symptoms. Some days after the onset of the clinical case, patient had urticarial lesions getting better while using loratadine. Complementary exams: RT PCR detectable, Thorax CT: ground-glass pattern taking 10% of the pulmonary tissue. Used drugs: chloroquine, azithromycin, zinc, oseltamivir.

Patient I

Man living in Altamira-PA, 28 years, without comorbidities. Reported dry caught, fever, myalgia, thoracic discomfort, fatigue, dysgeusia and anosmia. After this flu syndrome, related the emergence of erythematous plaques with papules compatible with disseminated maculopapular rash, without itch. Diagnosed with COVID-19 after the positive result in a fast test. Have not done complementary exams, only the fast test. Used medicines: prednisone, azithromycin, ivermectin, hydroxychloroquine e dipyrone.

Patient J

Patient living in Vitória do Xingu-PA, woman, 31 years, without comorbidities. Referred headache, myalgia, and fatigue for one week, associated with dry caught, during teen days, after the onset of flu syndrome, also had urticarial lesions with moderate itch, predominant in both legs. Curiously she had bruise lesions localized in the left arm. Diagnose positive for COVID-19 made with fast test. Physical exam: spO2 95%, HR: 115bpm, RR: 24bpm. Complementary exams: thorax CT with ground-glass pattern of lesions taking something about 20% of the lung tissue. Used drugs: chloroquine, azithromycin, oseltamivir.

Legend: FPG: fasting plasma glucose RBC: red blood cells, HT: hematocrit, HB: Hemoglobin, MCV: mean cell volume, MCH: mean cell hemoglobin corpuscular média, MCHC: Mean corpuscular hemoglobin concentration, RDW: red cell distribuition width, ESR: Erythrocyte sedimentation rate, ALT: alanine transaminase, AST: aspartate transaminase, ALP: Alkaline phosphatase, HDL:HDL-cholesterol, LDL: LDL-cholesterol, GGT: Gamma glutamyl transferase, DB: direct bilirubin, IB: indirect bilirubin,: CT: computed tomography, BPM: HR: heart rate, RR: respiratory rate.

RECIMA21 - REVISTA CIENTÍFICA MULTIDISCIPLINAR
ISSN 2675-6218



**TABLE I**- Classification of patients with COVID-19 according to epidemiologic and clinical characterises. Amazon, 2020.

| Patient | Sex | Age | Lesion pattern | Used drugs | Exam for COVID-19 | Thorax CT |
|---|---|---|---|---|---|---|
| **A** | Fem. | 42y | Urticarial | Pseudoephedrine + fexofenadine, azithromycin, paracetamol and multivitamin. | Serological | Haven't done |
| **B** | Fem. | 48y | Erytheme-papules (maculopapular rash), petechias | Haven't reported | Serological | Haven't done |
| **C** | Fem. | 41y | Pseudo-chilblain | azithromycin, ivermectin, chloroquine , paracetamol, enoxaparin. | Serological | Haven't done |
| **D** | Fem. | 33y | Punctate macules + Pseudo-chilblain | Painkillers | RT-PCR | Lesions taking< 5% |
| **E** | Male | 57y | Pseudo-chilblain | Losartan, metformin, painkillers. | Serological | Haven't done |
| **F** | Male | 30y | Urticarial | azithromycin, hydroxychloroquine prednisone | Serological | Normal |
| **G** | Fem. | 37y | Urticarial | Paracetamol | Serological | Lesions taking <5% |
| **H** | Male | 36y | Urticarial | chloroquine, azithromycin, zinc, oseltamivir. | RT-PCR | 10% acometimento |
| **I** | Male | 28y | Macules-papules | Prednisone, azithromycin, ivermectin, hydroxychloroquine, dipyrone. | Serological | Haven't done |
| **J** | Fem. | 31y | Urticarial Bruise | chloroquine, azithromycin, oseltamivir. | Serological | Something about 20% of affection |

Source: authors protocol

## DISCUSSION

The present serial cases report was realized in Amazon region, involving 10 patients, four mans and six women's, with ages varying between 28 and 57 years. Four lesion patterns were obtained, dividing patients into groups, being: (1) five patients with urticarial lesions (patients A, F, G, H and J); (2) three patients with pseudo-chilblains (patients C, E and D); (3) one patient with petechial and maculopapular rash (patient B); (4) three patients with maculopapular lesions (patients B, D and

RECIMA21 - REVISTA CIENTÍFICA MULTIDISCIPLINAR
ISSN 2675-6218



I). It should be noted that the patient D not only had punctate erythematous lesions, but also pseudo-chilblain, thus she was included in two groups. The same occurred with patient B, who had petechial and maculopapular lesions concomitantly. The discussion will be held according to these groups of patients, to make the relation between the findings of this study and those present in the literature more understandable, being carried out in the order already mentioned.

As of afore mentioned cases, a pattern of cutaneous involvement becomes evident, with a predominance of pruritic lesions, erythematous papular rash, petechial lesions, erythema compatible with pseudo-chilblains, punctate macules, with more frequent urticarial lesions. In addition, it is worth noting that the distribution of these lesions occurred in a variable way on the body surface and may appear before or after the specific symptoms of COVID-19.

Additionally, extremely important to elucidate in a comparative way the data found through this series of cases, and what is in evidence in the literature. In this way, it will be possible to verify the similarities and the existing contrasts. Therefore, the data will be discussed by groups of cutaneous manifestations, based on the clinical findings of this study.

In this context, according to the study of Casas et al. (2020), the founded lesions in the SARS-CoV-2 infection are classified in acral areas, containing erythema with vesicles or pustules (pseudo-chilblains) (19%), other vesicular eruptions (9%), urticarial lesions (19%), maculopapular rashes (47%) and livedo reticularis or necrosis (6%). With regard to period of onset, vesicular eruptions appear at the beginning of the disease (15% before other symptoms), pseudo-chilblains are later in the evolution of the disease (59% after other symptoms), and the remainder tends to appear associated with other symptoms of COVID-19.

Urticarial lesions were found in five of the ten patients (50%), representing the type of lesion most frequently founded in the present study (figures 1,2,3,4,5). Since the first report of dermatological lesions in patients with COVID-19, in Lombardy, Italy, urticaria has been implicated as a possible manifestation, being present in 3 of the 18 patients who had cutaneous manifestations [7]. Since then, the presence of urticarial lesions related to COVID-19 has been reported in several studies, reaching 19% of injuries in a study conducted with 375 patients [9].

At this juncture, the information that a viral infection could lead to the development of urticaria is not new, as several common viral infections are known to cause such a manifestation [10]. In addition, another common cause is the skin reaction after the use of some medicines, an important differential diagnosis in these cases [9]. In this context, it is possible that some patients have urticarial lesions after other symptoms, even if they are already using medications for the current disease. Furthermore, it is less common, but it is possible that cutaneous symptoms may precede the typical symptoms of COVID-19, in the absence of the use of new drugs at the time of the onset of these dermatologic lesions [10].

At that, and the patterns founded in these studies, a Spanish study suggested that because these lesions appear only after the other symptoms, added to the fact that they are a common

RECIMA21 - REVISTA CIENTÍFICA MULTIDISCIPLINAR
ISSN 2675-6218



manifestation of variable causes, they would most likely be of little use to be implicated in the patients' diagnosis[9]. It is worth mentioning that, in the present study, patients were not tested for other common viruses.

However, there are reports in the literature contrary to this conclusion, in which urticarial lesions: (1) appear as the only symptom, or only symptom associated with fever, in patients with laboratorial diagnose for COVID-19 [11]; (2) previously presented with other symptoms [12,13]; (3) they were presented in patients with laboratory confirmation of COVID-19, but who were tested negatively for other common viruses [11]; (4) they were manifested in patients who had not previously used new medications [11 12, 14, 15].

Another aspect studied of urticarial lesions is their correlation with the degree of the disease. Unlike pseudo-chilblains, which were consistently related to a milder pattern of involvement, urticarial lesions did not show this constancy in relation to the degree of the disease throughout the first reports [14]. On the other hand, a posted performed in their study, a gradual severity pattern within the five injury patterns established by them[9].

In this respect, those patients with urticarial lesions, together with those patients having maculopapular lesions, presented more severe disease compared to those patients with pseudo-chilblains or other vesicular lesions, however, lighter than in those patients with livedo [9]. In the present study, in addition to the variable degree of involvement of patients with urticarial lesions, the reduced number of patients does not allow us to carry out an assessment comparing the severity of patients with urticarial lesions, with those who had other types of injury.

In view of this, and according to the current context, it is essential that doctors recognize those patients who have urticarial lesions, without other more likely diagnostic hypothesis, therefore these patients should be investigated for SARS-CoV-2 infection and isolated, if necessary [12,13,14].

Three patients showed pseudo-chilblains, patients C and D on the hands (figures 6,7) and patients E on the feet (figure 8). This injury was associated with COVID-19 in previous studies [10,16]. However, patients C and E presented serology with IgM and IgG reagents for SARS-CoV-2, which was not possible in most of the previous studies, one of the reasons for the low availability of tests at that time [17].

In addition, a serial case report performed that RT-PCR exam with the sample collected using the nasopharyngeal swab of 11 patients having pseudo-chilblains and clinical diagnosis for COVID-19, founded a positive result in only two patients (18.1%). In contrast, patient D had this test as positive, however, patient D presented others skin manifestations concomitantly with pseudo-chilblains[21]. This low percentage of positive results, through RT-PCR, was shown to be present in other studies, which generated the need for further studies using serological tests and thus enabling a better understanding of this relation [18,19,20,21 22,23].

In addition, in previous studies, pseudo-chilblains showed a similar pattern in relation to the time of onset, prognosis and demographic factors. Lesions that appear late in the course of the

RECIMA21 - REVISTA CIENTÍFICA MULTIDISCIPLINAR
ISSN 2675-6218



disease are considered, with an average between 9,2-12,7 days since the onset of other symptoms, but can vary from 3-30 days, and with rare cases occurring simultaneously with the other symptoms. When assessing the prognosis of patients, it was repeatedly noted that those patients affected by this lesion had the mildest form of COVID-19 [9, 21].

Concomitantly, another case report using histopathologic findings suggested that the role of interferon type 1 (INF-1) in the response to SARS-CoV-2 and hypothesized that younger patients exhibit this response early, decreasing viral replication [17]. However, this response also produces microangiopathic changes, producing pseudo-chilblains. The decrease in viral replication added to the latency of the appearance of cutaneous symptoms, would partially explain the high number of negative RT-PCR results collected using the nasopharyngeal swab [21,22].

That way, it is worth mentioning that patients C, D and E presented similar patterns to those reported, with the appearance occurring after the other symptoms in patient C and D and with a late appearance (after four weeks) in patient E, all without complications and diverging from previous reports only in relation to age, as this pattern of lesion is primarily related to young patients and children [22,23]. The main symptoms associated with this injury are pain (32%) and pruritus (30%), with its present in patients C and E [9].

It should also be noted that pseudo-chilblains should not be confused with acral ischemia, due to thrombosis, observed in patients with more severe COVID-19, because while in patients with pseudo-chilblains usually have no complications and relevant laboratory changes, patients having acral ischemia are usually found in the intensive care unit, have hyper coagulopathy and elevated D-dimers [17].

In this perspective, Casas et al. (2020) suggest, based on their findings, that pseudo-chilblains have a greater value for epidemiological purposes than for diagnostic purposes, since they appear late in the course of the disease. In turn, the study using histopathologic founds showed attention to the observation that many young people with this lesion can be paucysymptomatic, but still a source of contagion, and should therefore be tested and isolated[17].

Patient B had petechial rashes (figures 9,10); a clinical finding often associated with Dengue. In this context, when patients with COVID-19 present a picture like the findings of other common diseases, there is difficulty to give an early diagnosis, because this condition can be easily confused with other endemic viruses. Likewise, early afebrile conditions can also contribute to a late diagnosis, increasing the risk of transmission and negative outcomes for the disease [24].

Similarly, macule-erythematous / maculopapular eruptions, found in patients B, D and I (figure 11), are common searches, because them should be caused by drugs, and be associated with other infections, bacterial and viral, especially when accompanied by other symptoms, such as fever, headache, muscle pain and breathing difficulties [10]. Maculopapular eruptions were the type of lesion most commonly found in two studies corresponding to 47% of the first one population, and in the second one, were found in 14 of the 18 patients[9,23].

RECIMA21 - REVISTA CIENTÍFICA MULTIDISCIPLINAR
ISSN 2675-6218



As such, it is noteworthy that the skin changes triggered by SARS-CoV-2 do not have their mechanisms well-defined, being largely linked to hypotheses. That way, a strong theory about the appearance of these skin lesions in COVID-19 is explained due to the reaction of viral particles contained in the blood vessels of the skin, producing responses that can cause changes, especially the vascular ones, and it is important to highlight the erythematous lesions [25,26]. It is also evident in the present study that a patient had an erythematous lesion on the face (Figure J).

## CONCLUSION

The present study evaluated patients with cutaneous manifestations associated with COVID-19, all cases were confirmed by laboratory, thus, contributing to reduce gaps pointed out by previous studies, mainly related to the lack of laboratory confirmation in patients with pseudo-chilblains. In agreement with the current literature, heterogeneous manifestations were found, with patterns of appearance and specific prognosis or, in some cases, not well determined [27,28,29]. The fact that all patients were selected based on the presentation of symptoms suggestive of COVID-19, as well as in most of the previous studies, did not allow us to contribute information about paucisymptomatic patients or those who have only cutaneous manifestations, but that can be a source of contagion, which makes it necessary for further studies to be carried out for this purpose.

## RECOMENDATION

The growing number of published works on the topic, such as case reports, histopathological studies and even works with national scope, are increasingly consolidating the association between COVID-19 and skin manifestations. That way, we hope that the present study contributes with the others researches and provides solid information to doctors base their assessment and management in relation to these patients.

RECIMA21 - REVISTA CIENTÍFICA MULTIDISCIPLINAR
ISSN 2675-6218



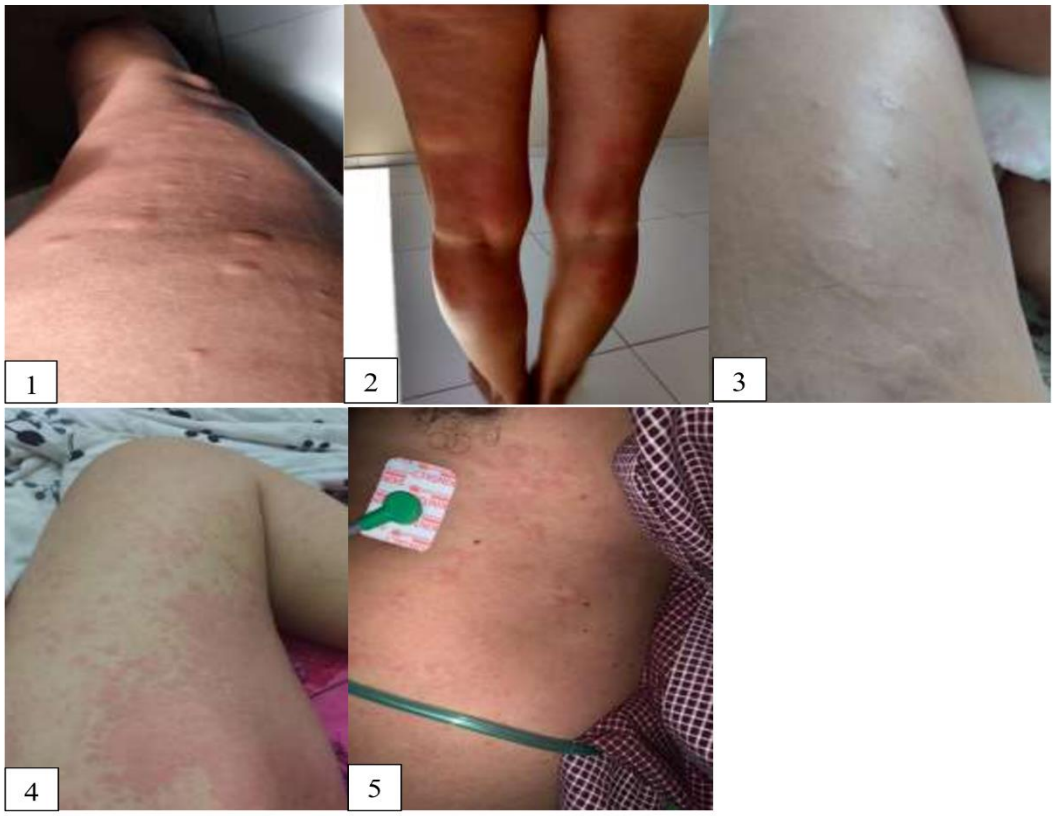


Figure 1- Urticarial lesions




Figure 2- Pseudo-chilblains

RECIMA21 - REVISTA CIENTÍFICA MULTIDISCIPLINAR
ISSN 2675-6218






Figure 3: rash maculopapular



Figure 4- bruise lesions, patient J.

RECIMA21 - REVISTA CIENTÍFICA MULTIDISCIPLINAR
ISSN 2675-6218



## REFERENCES

1. Wang C, Horby PW, Hayden FG, Gao GF. A novel coronavirus outbreak of global health concern. Lancet (London, England). 2020;395(10223):470-473.

2. BRASIL. Secretaria de Políticas de Saúde. Protocolo de manejo clínico do coronavírus (COVID-19) na atenção primária de saúde. Brasília, DF: Ministério da Saúde; 2020.

3. Chan FW, Shuofeng Y, Kin-Hang K, Kelvin KWT, Hin C, Jin Y, et al. A familial cluster of pneumonia associated with the 2019 novel coronavirus indicating person- to- person transmission: a study of a Family cluster. Lancet. 2020;395:514–523.

4. Rachael P, Calvin JC, Barnaby EY, Sarah C, Mark ICC, Hannah EC, et al. Investigation of three clusters of COVID-19 in Singapore:implications for surveillance and response measures. Lancet. 2020;395:1039–1046.

5. Li Q, Guan X, Wu P, Wang X, Zhou L, Tong Y, et al. Early Transmission Dynamics in Wuhan, China, of Novel Coronavirus-Infected Pneumonia. N Engl J Med. 2020 Mar 26;382(13):1199-1207. doi: 10.1056/NEJMoa2001316. Epub 2020 Jan 29. PMID: 31995857; PMCID: PMC7121484.

6. Daniel B, Maria JS, Matthew AS, Swapnil H, Andrew MS, Paul AW, et al. Acute Kidney Injury in COVID-19: Emerging Evidence of a Distinct Pathophysiology. 2020 may. ASN.2020040419.

7. Recalcati S, Barbagallo T, Frasin LA, Prestinari F, Cogliardi A, Provero MC, et al. Acral cutaneous lesions in the time of COVID-19. J Eur Acad Dermatol Venereol. 2020 Apr 24:10.1111/jdv.16533. doi: 10.1111/jdv.16533. Epub ahead of print. PMID: 32330324; PMCID: PMC7267354.

8. Bursal DB, Yozgat CY, Yozgat Y, Turel O. Appearance of skin rash in pediatric patients with COVID-19: Three case presentations. Dermatol Ther. 2020 May 15:e13594. doi: 10.1111/dth.13594. Epub ahead of print. PMID: 32412681; PMCID: PMC7261998.

9. Galván CC, Català A, Carretero HG, Rodríguez-Jiménez P, Fernández-Nieto D, Rodríguez-Villa Lario A, et al. Classification of the cutaneous manifestations of COVID -19: a rapid prospective nationwide consensus study in Spain with 375 cases. Br J Dermatol. 2020;183:71-77. doi:10.1111/bjd.19163

10. Elmas ÖF, Demirbaş A, Özyurt K, Atasoy M, Türsen Ü. Cutaneous manifestations of COVID-19: A review of the published literature. Dermatol Ther. 2020 May 26:e13696. doi: 10.1111/dth.13696. Epub ahead of print. PMID: 32458546; PMCID: PMC7283644.

11. QUINTANA-CASTANEDO L. et al. Urticarial exanthem as early diagnostic clue for COVID-19 infection. JAAD Case Rep. Abr. 2020;6(6):498-499.

12. Van DC, Berlingin E, Saussez S, Accaputo O. Acute urticaria with pyrexia as the first manifestations of a COVID-19 infection. J Eur Acad Dermatol Venereol. 2020 Apr 24:10.1111/jdv.16523. doi: 10.1111/jdv.16523. Epub ahead of print. PMID: 32329915; PMCID: PMC7264566.

13. Henry D, Ackerman M, Sancelme E, Finon A. and Esteve, E. Urticarial eruption in COVID-19 infection. J Eur Acad D, et al. Dermatol Venereol. 2020;34:e244-e245. doi:10.1111/jdv.16472.

14. Gunawan C, Angela A; Widysanto A. Urticarial eruption in coronavirus disease 2019 infection: a case report in Tangerang, Indonesia. J Eur Acad Dermatol Venereol. 2020 Maio.

RECIMA21 - REVISTA CIENTÍFICA MULTIDISCIPLINAR
ISSN 2675-6218



15. Rivera-Oyola R, Koschitzky M, Printy R, Liu S, Stanger R, Golant A, et al. Dermatologic findings in two patients with COVID-19. JAAD Case Rep. 2020 Apr 28;6(6):537–9. doi: 10.1016/j.jdcr.2020.04.027. Epub ahead of print. PMID: 32346588; PMCID: PMC7187826.

16. Marzano AV, Cassano N, Genovese G, Moltrasio C, Vena GA. Cutaneous manifestations in patients with COVID-19: A preliminary review of an emerging issue. Br J Dermatol. 2020 Jun 1:10.1111/bjd.19264. doi: 10.1111/bjd.19264. Epub ahead of print. PMID: 32479680; PMCID: PMC7300648.

17. Kolivras A, Dehavay F, Delplace D, Feoli F, Meiers I, Milone L, et al. Coronavirus (COVID-19) infection-induced chilblains: A case report with histopathologic findings. Version 2. JAAD Case Rep. 2020 Apr 18;6(6):489–92. doi: 10.1016/j.jdcr.2020.04.

18. Andina D, Noguera-Morel L, Bascuas-Arribas M, Gaitero-Tristán J, Alonso-Cadenas JA, Escalada-Pellitero S, et al. Chilblains in children in the setting of COVID-19 pandemic. Pediatr Dermatol. 2020 May;37(3):406-411. doi: 10.1111/pde.14215. Epub 2020 May 22. PMID: 32386460; PMCID: PMC7272985.

19. BOUAZIZ JD. et al. Vascular skin symptoms in COVID-19: a French observational study. J Eur Acad Dermatol Venereol. 2020 Abr.

20. DOCAMPO-SIMÓN A, et al. Are chilblain-like acral skin lesions really indicative of COVID-19? A prospective study and literature review. J Eur Acad Dermatol Venereol. 2020 Maio

21. Fernandez-Nieto D, Jimenez-Cauhe J, Suarez-Valle A, Moreno-Arrones OM, Saceda-Corralo D, Arana-Raja A, et al. Characterization of acute acral skin lesions in nonhospitalized patients: A case series of 132 patients during the COVID-19 outbreak. J Am Acad Dermatol. 2020 Jul;83(1):e61-e63. doi: 10.1016/j.jaad.2020.04.093. Epub 2020 Apr 24. PMID: 32339703; PMCID: PMC7195051.

22. El Hachem M, Diociaiuti A, Concato C, Carsetti R, Carnevale C, Ciofi Degli Atti M, et al. A clinical, histopathological and laboratory study of 19 consecutive Italian paediatric patients with chilblain-like lesions: lights and shadows on the relationship with COVID-19 infection. J Eur Acad Dermatol Venereol. 2020 May 31:10.1111/jdv.16682. doi: 10.1111/jdv.16682. Epub ahead of print. PMID: 32474947; PMCID: PMC7301001.

23. RECALCATI S. Cutaneous manifestations in COVID-19: a first perspective: a first perspective. Journal Of The European Academy Of Dermatology And Venereology, [s.l.], p. 18-22, 26 mar. 2020. Wiley. http://dx.doi.org/10.1111/jdv.16387.

24. Joob B, Wiwanitkit V. COVID-19 can present with a rash and be mistaken for dengue. Journal Of The American Academy Of Dermatology. 2020 Maio;82(5):177. Elsevier BV. http://dx.doi.org/10.1016/j.jaad.2020.03.036.

25. Sachdeva M, Gianotti R, Shah M, Bradanini L, Tosi D, Veraldi S, et al. Cutaneous manifestations of COVID-19: Report of three cases and a review of literature. J Dermatol Sci. 2020 May;98(2):75-81. doi: 10.1016/j.jdermsci.2020.04.011. Epub 2020 Apr 29. PMID: 32381430; PMCID: PMC7189855.

26. Gianotti R, Zerbi P, Dodiuk-Gad R. Histopathological study of skin dermatoses in patients affected by COVID-19 infection in the Northern part of Italy. Journal of Dermatological Sciences. 2020.

27. Criado PR. Manifestações de pele devido à COVID-19 causada pelo vírus SARS-CoV-2: uma interpretação dos dados frente à luz dos fatos até o dia 26 de março de 2020. Sociedade Brasileira de Dermatologia. 2020. [acesso em 2020 july 16] Disponível em:

RECIMA21 - REVISTA CIENTÍFICA MULTIDISCIPLINAR
ISSN 2675-6218



https://www.sbd.org.br/noticias/manifestacoes-na-pele-devido-a-covid-19-causada-pelo-virus-sars-cov-2-uma-interpretacao-dos-dados-frente-a-luz-dos-fatos-ate-o-dia-26-de-marco-de-2020/.

28. Magro C, Mulvey JJ, Berlin D, Nuovo G, Salvatore S, Harp J, et al. Complement associated microvascular injury and thrombosis in the pathogenesis of severe COVID-19 infection: A report of five cases. Transl Res. 2020 Jun;220:1-13. doi: 10.1016/j.trsl.2020.04.007. Epub 2020 Apr 15. PMID: 32299776; PMCID: PMC7158248.

29. Fernandez-Nieto D, Ortega-Quijano D, Segurado-Miravalles G, Pindado-Ortega C, Prieto-Barrios M, Jimenez-Cauhe J. Comment on: Cutaneous manifestations in COVID-19: a first perspective. Safety concerns of clinical images and skin biopsies. J Eur Acad Dermatol Venereol. 2020 Jun;34(6):e252-e254. doi: 10.1111/jdv.16470. Epub 2020 Jun 4. PMID: 32294262; PMCID: PMC7262048.