REVISTA CIENTÍFICA - RECIMA21 ISSN 2675-6218

SURGICAL PLANNING - 3D VIRTUAL REHABILITATION OF A SEVERELY WORN DENTITION: CASE REPORT

PLANEJAMENTO CIRÚRGICO - REABILITAÇÃO VIRTUAL 3D DE DENTIÇÃO COM DESGATE SEVERO: RELATO DE CASO

PLANIFICACIÓN QUIRÚRGICA - REHABILITACIÓN VIRTUAL 3D DE DENTICIÓN GRAVEMENTE DESGASTADA: REPORTE DE CASO

Waleska Caldas[1], Hugo Rodrigo Velasco Iriarte[2], Claudia Cecilia Velasco Iriarte[2], Mónica Tatiana Velasco Iriarte[2], Maria Fernanda Pivetta Petinati[3]

e666475
https://doi.org/10.47820/recima21.v6i6.6475

RECEIVED: 04/15/2025 APPROVED: 05/15/2025 PUBLISHED: 06/01/2025

ABSTRACT
This case report presents the successful use of 3D Virtual Surgical Planning-Rehabilitation (3D VSPR) and Computer-Aided Design/Computer-Aided Manufacturing (CAD/CAM) during provisional and final stages of complex and complete oral rehabilitation treatment in a patient with severely worn-down dentition. This case shows the benefits of facial and intraoral scans to create a digital case model and profile throughout the various stages of implant treatment planning and successful implant placements. The use of such digital advances in Implantology in this case, demonstrates successful long-lasting, esthetic, and functional results after a 24-month follow-up. Using proper healing methods and occlusal splints to control parafunctional habits, this case also shows no further evidence of bone loss, tooth wear, or loss of Vertical Dimension of Occlusion (VDO) in the patient. The approach through a digital workflow for oral rehabilitation of severely worn-down dentition favors a less invasive, accurate, and predictable outcome in complex oral rehabilitation treatment.

KEYWORDS: CAD/CAM. Digital planning. Parafunctional habits. Dental implants.

RESUMO
Este relatório de caso apresenta o uso exitoso do planejamento-reabilitação cirúrgica virtual 3D (3D VSPR) e o projeto/fabricação assistida por computador (CAD/CAM) durante as etapas provisórias e finais de um tratamento de reabilitação oral complexo e completo em um paciente com dentição com grave desgaste. Este caso mostra os benefícios dos escaneamentos faciais e intraorais para criar um modelo e perfil de caso digital ao longo das etapas separadas do planejamento do tratamento com implantes e da instalação existente de implantes. O uso destes avanços digitais em implantodontia, neste caso, demonstra resultados positivos, duradouros, estéticos e funcionais após um acompanhamento de 24 meses. Utilizando métodos de cicatrização adequados e placas oclusais para controlar os hábitos parafuncionais, este caso também não mostra evidências de perda óssea, desgaste dentário ou perda da Dimensão Vertical de Oclusão (VDO) no paciente. A abordagem através de um fluxo de trabalho digital para a reabilitação oral da dentição severamente desgastada, favorecendo um resultado menos invasivo, preciso e previsível em um tratamento de reabilitação oral complexo.

PALAVRAS-CHAVE: CAD/CAM. Planejamento digital. Hábitos parafuncionais. Implantes dentários.

[1] DDS, MSc, PhD. Clinical Affairs & Biocomp Director at Neodent, Curitiba, Brazil.
[2] DDS, Private Clinic, Cochabamba, Bolivia.
[3] DDS, MSc, PhD. Research Specialist at Neodent, Curitiba, Brazil.

REVISTA CIENTÍFICA - RECIMA21 ISSN 2675-6218

RESUMEN
Este informe de caso presenta el uso exitoso de la planificación-rehabilitación quirúrgica virtual 3D (3D VSPR) y el diseño/fabricación asistida por computadora (CAD/CAM) durante las etapas provisionales y finales de un tratamiento de rehabilitación oral complejo y completo en un paciente con dentición gravemente desgastada. Este caso muestra los beneficios de los escaneos faciales e intraorales para crear un modelo y perfil de caso digital a lo largo de las distintas etapas de la planificación del tratamiento con implantes y la colocación exitosa de implantes. El uso de estos avances digitales en Implantología, en este caso, demuestra resultados exitosos, duraderos, estéticos y funcionales después de un seguimiento de 24 meses. Utilizando métodos de curación adecuados y férulas oclusales para controlar los hábitos parafuncionales, este caso tampoco muestra más evidencia de pérdida ósea, desgaste dental o pérdida de la Dimensión Vertical de Oclusión (VDO) en el paciente. El enfoque a través de un flujo de trabajo digital para la rehabilitación oral de dentición severamente desgastada favorece un resultado menos invasivo, preciso y predecible en un tratamiento de rehabilitación oral complejo.

PALABRAS CLAVE: CAD/CAM. Planificación digital. Hábitos parafuncionales. Implantes dentales.

INTRODUCTION

One of the most challenging situations in fixed prosthetic oral rehabilitation is cases involving excessive dental wear. In many cases, a patient's vertical dimension would require multiple adjustments throughout the treatment phases. With new 3D hardware such as CAD/CAM and other software tools, a more accurate and predictable treatment planning is accomplished, reducing cases that fail over time [1].

In Oral Maxillofacial Surgery, 3D VSPR is gaining prominent interest and modalities of usage [2]. 3D VSPR has made it easier to design and 3D print surgical guides, which has increased the successful outcomes of various complex procedures. These procedures include osteotomy reductions, extractions of complex retained teeth, removal of osteolytic lesions, maxillary sinus lifts, and the placement of dental implants. In terms of implants, these 3D surgical guides have consistently shown higher success rates for conventional and zygomatic implant placements and their definitive restorations [3-5].

Implant placement using 3D image-guided technologies is now a clinical reality. Such technology offers advantages in accuracy and favorable definitive results for complex and minimally invasive procedures [6]. Although new digital 3D software provides favorable outcomes, many factors can limit the use of these programs to some extent. One of these limits is the positional variations that may occur due to a lack of scanning detail caused by the "snowball" effect with 3D Scanners and their programs. Although these limitations may be inevitable at times, 3D image-guided surgical implant treatment planning still provides safer surgeries and lower grafting rates in patients [7].

The Digital Workflow includes the use of three-dimensional images obtained through Cone Beam Computed Tomography CBCT (DICOM format file) and digitalization of the oral cavity (STL

format file). It also includes the use of software to assist in treatment planning. This planning allows for prototyping using 3D printers or milling systems, making it possible to produce mockup models accessible for oral rehabilitation [8-9].

This case report presents a complex and complete oral rehabilitation of a patient with severely worn dentition. The treatment rendered uses CAD/CAM facial and intra-oral scans and protocols to create a complete digitalization of the patient's face and dentition. These digital and 3D models are then used for the successful surgical placement of implants for provisional and definitive restorations.

CLINICAL CASE

A 75-year-old male patient with no concern medical history and in general good health presented himself for full-mouth rehabilitation. The patient's main complaint was difficulty with chewing and speech imparities due to severely worn-down dentition and edentulous areas. A complete oral and periodontal evaluation provided a diagnosis of generalized gingivitis with localized severe periodontitis of the lower anterior with grade 4 mobility. In addition, multiple upper and lower edentulous areas were noted alongside a reduced occlusal plane. The patient presented with normal buccal mucosa and no other significant changes in the oral cavity (Figure 1).

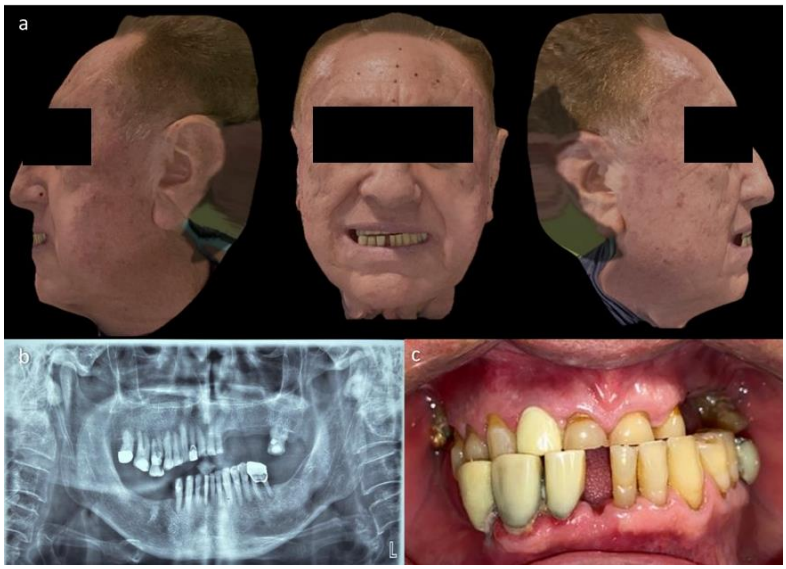

Figure 1. a) Face scan. b) Pre-operative panoramic radiograph. c) Pre-operative clinical demonstration showing significant reduction of vertical dimension due to tooth wear.

The treatment plan consisted of proper oral disease-controlling phases to allow way for the digitization of the patient for complete oral rehabilitation. The initial phase consisted of improving gingival and periodontal health with scaling and root planning of all four quadrants and daily chlorhexidine 12% gluconate prescription rinses.

REVISTA CIENTÍFICA - RECIMA21 ISSN 2675-6218

Extractions were carried out to eliminate the remaining infectious foci. The reconstructive treatment planning phase included a 3D smile design, gingivectomies, and proper implant-guided planning on digital CAD/CAM software. On the maxilla, it was planned to place implants in the upper left edentulous area alongside his remaining natural dentition. On the mandible, a six-implant hybrid denture prosthesis was planned to be placed. The patient presented with no contraindications on his medical history that would prohibit such treatments from being rendered.

3D planning and CAD/CAM fabrication of surgical guides, crowns and provisional lower hybrid prosthesis

After a complete clinical and radiographic exam, proper steps were taken to allow complete digitization and case mock-ups of the patient profile and dentition. These steps included a patient´s facial scan (Bellus3D Face App; Bellus3D Inc, Los Gatos, Calif), a mesio-facial CBCT (Promax 3D; Planmeca, Helsinki, Finland), as well as scanning of study models (AutoScan-DS-EX; Shining 3D Tech Co, Hangzhou, China) both in conventional articulation and on semi-adjustable articulators (Bioart A7plus; São Carlos, São Paulo, Brazil).

The study model scans produced STL images imported into a surgical planning computerized software (Blue Sky Plan; Blueskybio.com, Blue Sky Bio®) and then aligned with DICOM images obtained from the CBCT (Figure 2).

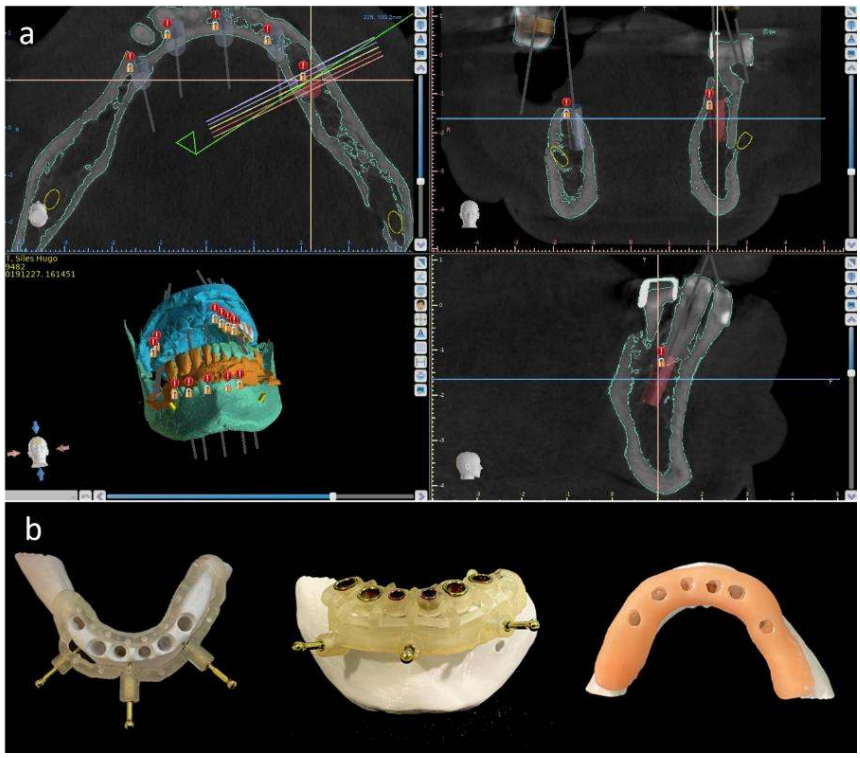

Figure 2. a) Virtual surgical planning. b) Stereolithographic models with osteotomy guides and 3D-guided implants

REVISTA CIENTÍFICA - RECIMA21 ISSN 2675-6218

A 3D smile design was created to present the final restorative outcome to the patient as well as establish proper lengths and esthetics. 3D Surgical osteotomy and gingivectomy guides were created for proper crown lengthening and gingival contouring procedures of the residual maxillary dentition (Figure 3). In addition to these guides, the 3D smile design allowed the digital planning of provisional crowns using the open software Meshmixer ™ (Autodesk ®, Inc., San Rafael, CA, USA).

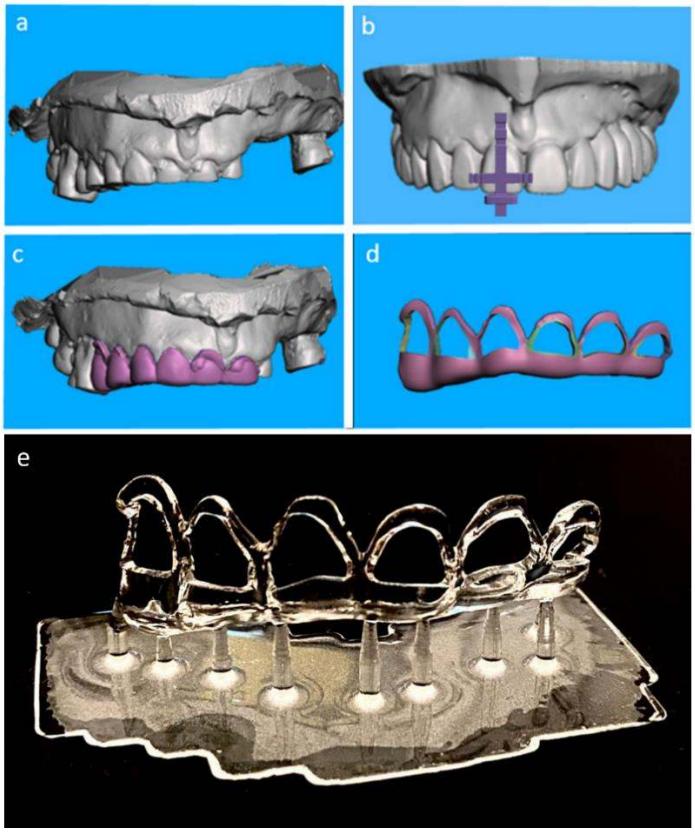

Figure 3. a) Initial digital model b) Smile design and digital wax-up c) Gingivectomy planning d) Gingivectomy and maxillary anterior osteotomy guide e) 3D printed surgical guide

The ideal implant position was virtually planned and prosthetically surgically guided. The 3D surgical guides and provisionals were printed on a rapid prototyping machine (Anycubic Photon; Anycubic Inc., Shenzhen, China) (Figure 2b).

For the maxillary arch, the surgical implant dimensions were virtually planned. Three CM Drive Acqua Implant 4.3x11.5 mm (Neodent, Curitiba, Brazil) were planned in the upper right first and second molar with extractions on the same day and in the upper left canine. Additionally, two CM Drive Acqua Implant 3.5x11.5 mm (Neodent, Curitiba, Brazil) were projected in the upper left first and second premolar.

REVISTA CIENTÍFICA - RECIMA21 ISSN 2675-6218

For the mandibular arch, proper planning was done to correct the occlusal cant via 3D surgical osteotomy guide. Once proper occlusion was established, 6 implants were digitally planned for the mandible. The implant dimensions were virtually designed using various 3D software specializing for each tooth type. Two CM Drive Acqua Implant 4.3x13 mm (Neodent, Curitiba, Brazil), two CM Drive Acqua Implant 4.3x11.5 mm (Neodent, Curitiba, Brazil), and two CM Drive Acqua Implant 3.5x13 mm (Neodent, Curitiba, Brazil) were planned for canines, premolars, and lower anterior regions, respectively. A provisional mandibular hybrid prosthesis was also planned in paid software (Exocad, Dental CAD Software, GmbH; Fraunhofer IGD, Darmstadt, Germany) (Figure. 4).

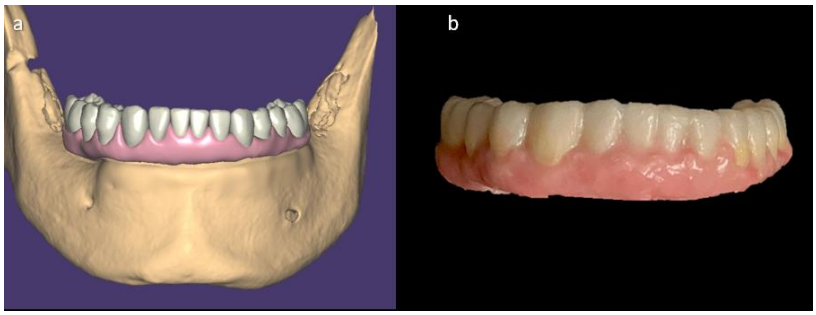

Figure 4. 3D Planning and milled lower hybrid provisional prostheses

Surgical procedure

The treatments were performed in several stages and appointments. Local anesthesia was achieved using 2% Lidocaine with 1:100K epinephrine. The 3D printed surgical guide (jig-saw type, as it presented an accessible window on the upper right due to the supra-erupted 1st and 2nd molar condition) was fitted on the patient's mouth. Precise adaptation and accuracy of the guide on the patient's dentition were confirmed prior to surgical implant placement on the upper left. Using the 3D milled surgical guides and following the implant placement manufacturer protocol, the implant placement on the upper left was performed using a flapless surgery in the position corresponding to those planned with the surgical guide. The implants were torqued to their ideal 35 N/cm per the manufacturer's protocol. Once the surgical guide was safely removed from the surgical site, healing abutments were placed with no additional suturing required (Figure 5).

REVISTA CIENTÍFICA - RECIMA21 ISSN 2675-6218



Figure 5. a) Surgical guide showing "jigsaw puzzle" access for upper right implants, b) Flapless surgically guided implant placement

At the second appointment, treatment was focused on extractions of the upper right molars with immediate implant placements. Local anesthesia of the upper right was achieved using 2% lidocaine with 1:100K epinephrine. Atraumatic extractions of the first and second molars were performed, followed by proper curettage and debridement of surgical sites. The drilling was performed according to the manufacturer's protocol and a surgical jig-saw guide was 3D-printed (Cosmos SG; Yller Biomaterials SA, Pelotas, Brazil). A resorbable collagen membrane was placed over the surgical site using 4-0 Nylon sutures to aid with proper bone regeneration. After one week, those sutures were removed, and healing with no signs of infection was clinically observed.

The third appointment consisted of crown lengthening involving osteotomy and gingival contouring following the proper 3D smile design created and using a 3D printed osteotomy guide (Cosmos SG, Yller Biomaterials SA, Pelotas, Brazil). Under local anesthesia, the osteotomy guide was placed intraorally and the gingivectomy of the maxillary anterior regions was performed using electrosurgery. Once proper gingival height was established, osteotomy and bone recontouring were performed 2 mm above the final gingival height. The surgical guide was removed, and the gingival flap was sutured with 4-0 Nylon repositioning it to the ideal position (Figure 6). After one week of healing, the sutures were removed, and proper endodontic and crown preparations were performed on the residual maxillary teeth. Provisional A3 shade resin crowns were 3D printed and temporarily cemented on the maxillary crown-prepared teeth to aid aesthetics and function (Cosmos temp A2, Yller Biomaterials SA, Pelotas, Brazil; Cosmos creation, Yller Biomaterials SA, Pelotas, Brazil) (Figure 7).

REVISTA CIENTÍFICA - RECIMA21 ISSN 2675-6218

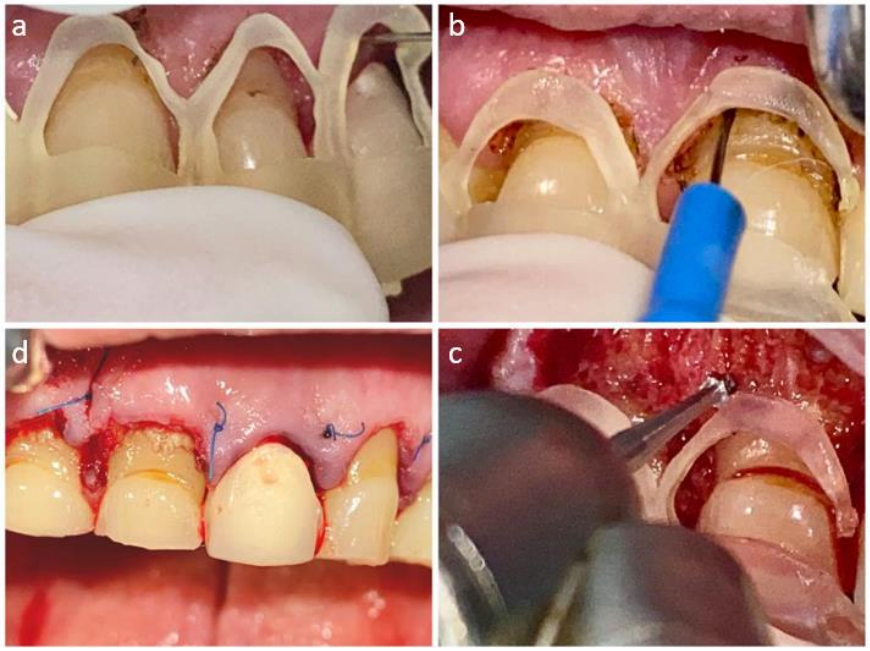

Figure 6. a) Intra-oral testing of 3D printed guides. b). Gingivectomy with mono-polar electrosurgery c). Osteotomy. d) Flap repositioning with simple sutures



Figure 7. a) Esthetically stained temporaries. b) Crown prepping and cementation of 3D-printed provisional prostheses

The fourth appointment focused on the mandibular arch treatment with complete mandibular tooth extractions. Local anesthesia of the mandible was achieved using 4% Articaine with 1:100K Epinephrine following proper anesthetic protocols. A 3D-printed positioning guide was placed over the existing mandibular teeth to confirm the surgical guide's accuracy.

REVISTA CIENTÍFICA - RECIMA21 ISSN 2675-6218

Once the guide adaptation was confirmed, an intra-cervical pocket flap with bilateral distal extensions was performed allowing proper visualization of the remaining mandibular dentition and their roots. First molar, first premolar, second premolar, canine, lateral incisor, and central incisor atraumatic extractions were performed on the lower left hemiarch. On the other hand, first premolar, canine, lateral incisor, and central incisor atraumatic extractions were performed on the lower right hemiarch. After all teeth extraction, a 3D printed osteotomy guide was placed and fitted to perform alveoloplasty and correct the occlusal cant. A mucogingival subperiosteal flap was reflected to properly place and secure the osteotomy guide (Cosmos SG, YIler Biomaterials SA, Pelotas, Brazil) to the mandible with 3 vestibular fixation pins through their designated access holes. Using the osteotomy surgical guide as a reference, piezoelectric surgery (Mectron Piezosurgery Device, Mectron, Genova, Italy) was used to perform an alveoloplasty and to level the mandibular bone correcting the previously presented occlusal cant.

Once the occlusal cant was corrected, the procedure was focused on surgical implant placement in the mandibular arch. A 3D-printed surgical guide was securely placed to aid the surgical placement of 6 implants. Following Branemark and implant manufacturer protocols, proper implant drills and lengths were used for the implants placed in the edentulous areas (Figure 8).

REVISTA CIENTÍFICA - RECIMA21 ISSN 2675-6218

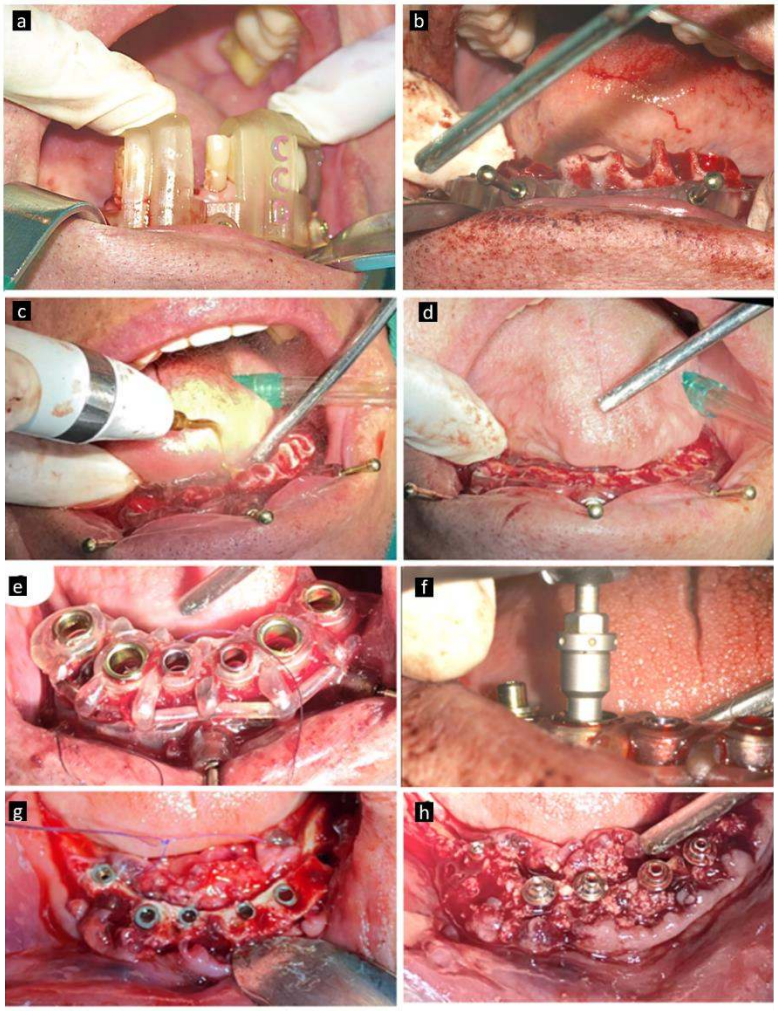

Figure 8. a) Positioning guide on the natural mandibular dentition. b) Atraumatic extractions and secured osteotomy guide with vestibular fixation pins. c) Guided osteotomy using piezoelectric handpiece. d) Occlusal cant correction. e) 3D Implant Surgical Guide. f) Guided implant placement of 6 mandibular implants. g) Final position of the implants. h) Multi-unit abutments placed.

Following the 6 mandibular implant placements, CM Multi-Unit Rotational Abutments (MUA) (Neodent, Curitiba, PR, Brazil) were placed with their Healing Abutments (Neodent, Curitiba, PR, Brazil). Guided bone regeneration was followed and a resorbable membrane was placed using polyglactin 910 (PGLA) sutures. Post-surgical indications of corticosteroids and intramuscular analgesics were followed and provided. Oral analgesics and antibiotic therapy were also provided to prevent post-op infections. A mixture with 0.2% Chlorhexidine digluconate gel and 1% hyaluronic acid was applied topically to the suture sites for two weeks. Following 10 days, the PGLA sutures were removed following proper and favorable healing.

Forty-eight hours after suture removal, the treatment focused on the designing and printing the provisional prosthesis for the mandibular arch.

REVISTA CIENTÍFICA - RECIMA21 ISSN 2675-6218

Using Exocad dental software (Exocad, Darmstadt, Germany), a 3D mandibular implant-overdenture hybrid temporary prosthesis was milled and placed over the 6 mandibular implants. The prosthesis was adapted to the MUA Rotational Abutments and allowed for passive insertion to the implants. The provisional denture teeth were shade-matched and pink resin was added for a gingival appearance (Cosmos denture, Yller Biomaterials SA, Pelotas, Brazil). Occlusal adjustments to the temporary prosthesis were rendered for esthetics and function as needed for the opposing maxillary temporary crowns (Figure 9).



Figure 9. Provisionals in mouth

After 6 months of provisional prostheses placement, clinical and radiographic follow-up examinations were performed (

Figure **10**). Using the temporary prosthesis as a template, full mouth digital intraoral scans (3Shape TRIOS, Copenhagen, Denmark) were done to facilitate the digital design of final maxillary crowns and the mandibular implant-overdenture prosthesis. The final scan of the maxillary crown preparation using TRIOS Scanner allowed 3D Zirconia crowns to be designed and milled with exact precision and marginal fit (Figure 11). A final mandibular scan using intraoral implant scanbodies allowed the mandibular implant-overdenture to be milled using a polyetheretherketon (PEEK) base and PEEK prepped abutments (Figure 12). These prepped abutments were scanned, and the final crowns were 3D-designed. Final mandibular zirconia crowns were then milled and cemented over the prepped abutments (Figure 13).

REVISTA CIENTÍFICA - RECIMA21 ISSN 2675-6218



Figure 10. Clinical and radiographic control after 6 months of provisional prosthesis placement



Figure 11. a) Digital scan of the provisional prosthesis. b) Mandibular scan using intraoral scanbodies. c) Milled final zirconia crowns and zirconia implant crowns

REVISTA CIENTÍFICA - RECIMA21 ISSN 2675-6218



Figure 12. Milled mandibular PEEK bar and prepped PEEK abutments; Zirconia crowns cemented over PEEK abutments



Figure 13. Final rehabilitation

At 24 months, clinical and radiographic follow-up examinations were performed alongside a dental cleaning. Removal of the mandibular hybrid prosthesis for its proper cleaning and evaluation was rendered. The exam showed no significant findings to tissue health, implant stability, or advances to previous periodontal conditions (Figure and Figure 14).

REVISTA CIENTÍFICA - RECIMA21 ISSN 2675-6218

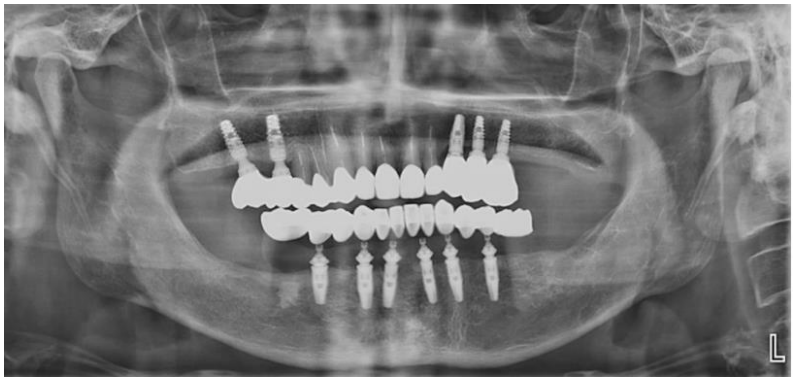

Figure 14. Radiographic control at 24-month final prosthesis follow-up

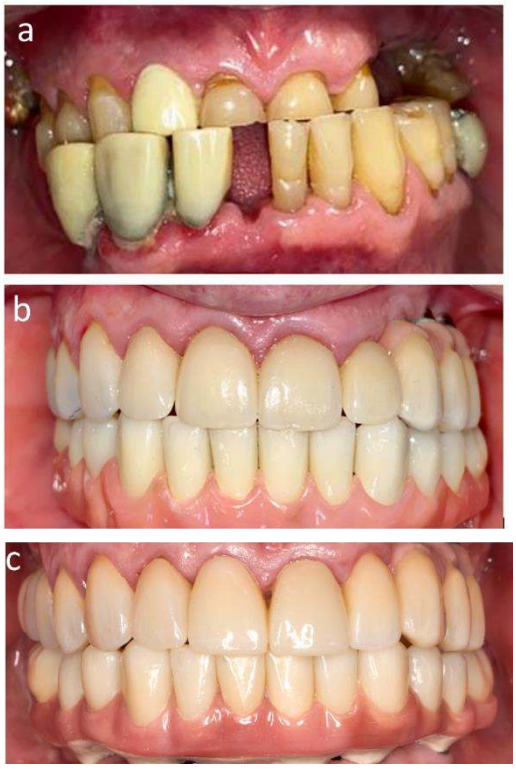

Figure 14. a) Initial. b) 6-month provisional prosthesis follow-up. c) 24-month final prosthesis follow-up

DISCUSSION

The presented case protocol is proposed to overcome the main challenges that may occur with severely compromised and worn dentition during implant-supported oral rehabilitations in both fully edentulous and partially bilateral maxillary edentulous patients. Digital dentistry is a ubiquitous phenomenon these days. The use of intraoral and facial scanners, CBCT, CAD/CAM, surgical guides, 3D printers, and new reinforced dental esthetic materials has substantially transformed conventional implant dental treatment [8]-[9]. However, technological advances also present a

challenge for the dental professional, as there is a constant need to learn how to operate new devices, software, machines, and as well as how to integrate them into daily practice [10-12].

Rehabilitation on bilateral maxillary implants in both partially and fully edentulous patients presents challenges because of the changes that occur to the edentulous ridge. These changes are related to continuous bone resorption, maxillary sinus pneumatization, supra-eruption of dentition, and mesial/distal tipping of neighboring teeth. These can be progressed by other factors such as poor oral hygiene, parafunctional bruxism habits, and VDO changes increasing to temporomandibular dysfunction (TMD) [13-15].

3D VSPR use is justified consistently because of the advantages it provides for surgical complex procedures. On the other hand, there is controversy about its usefulness in simple and less invasive procedures.

Factors such as operator experience and cost-benefit ratio all add to these negative notions [16]. The placement of single tooth implants in favorable areas normally does not justify the use of 3D surgical guides and digital planning, but it may have a positive benefit for inexperienced surgeons as it provides safer and more favorable results. In more complex cases such as zygomatic implant placement, 3D VSPR is very efficient for preoperative planning but may reduce the surgeon's skills intraorally due to the inherent difficulties and steps of placement with prefabricated guides [17-19].

Despite the possible cost limitation, the price of 3D technology continues to decrease in terms of devices, materials, and software available. Implementation costs can be reduced by outsourcing the work to be performed, without the need for the extra training that comes with 3D VSPR A review of virtual planning software for guided implant surgery-data import and visualization, drill guide design and manufacturing [18]. However, it would be more objective to evaluate these topics using some cost-efficiency methods. In an investigation carried out by Joda and Brägger (2014), evidence showed that digital workflow was more efficient than the conventional path established for implant-supported crowns [20].

In summary, 3D VSPR and CAD/CAM technologies present extraordinary advantages in many types of surgical interventions [7]. This technology provides the clinician with exact knowledge of the surgical procedure, greatly reducing the margin of error. It is important to consider the "snowball" effect that can creep into each protocol step [21]. In addition, it offers new perspectives that facilitate the achievement of high-quality restorations with high aesthetic compromise in a shorter time [22].

Overall, the patient's chief complaints were resolved in this case report. The patient was satisfied with the function and overall aesthetic results of the treatment. After a 2-year follow-up, there was no evidence of bone loss, VDO loss, or progressive tooth wear. To maintain these positive outcomes, the patient uses an occlusal splint to control bruxism and avoid further tooth wear.

REVISTA CIENTÍFICA - RECIMA21 ISSN 2675-6218

This case report presents inherent limitations that must be considered. As it describes the clinical outcome of a single patient, the results cannot be generalized to the wider population. The lack of a control group and the individualized nature of the follow-up introduce potential biases and limit the strength of the conclusions. To confirm the effectiveness and broader applicability of the proposed protocol, further research involving larger sample sizes and more rigorous study designs is necessary.

CONCLUSION

There are pros and cons to 3D planning and surgical guide use for implant placements. 3D VSPR and CAD/CAM decrease surgical time in overall cases, but the pre-operative steps required to create and mill surgical guides are more time-consuming than conventional surgical methods.

The time spent pre-operatively is compensated by the simplification, reduced surgical time intraorally, and more predictable surgical outcomes in complex oral rehabilitation cases. Another positive benefit is the evidence of significantly reduced post-operative recovery times, especially in patients with underlying conditions contraindicating limitations for surgeries.

3D VSPR provides exhaustive preoperative information, allowing the surgery simulation on a digital platform and moving from digital to reality through stereolithography. The surgeons have the opportunity to analyze, predict, anticipate, and prevent surgical and prosthetic rehabilitation complications leading to successful results with a high degree of function and reduced overall case failures.

REFERENCES

[1] Jennes ME, Mehrhof J, Strietzel FP, Schwendicke F, Herbst S, Spies B. Digital treatment planning and prosthetic rehabilitation of a patient suffering from generalized tooth wear. Dtsch Zahnärztl Z Int. 2020;2:73-81.

[2] Van Noort R. The future of dental devices is digital. Dental materials. 2012;28(1):3-12. https://doi.org/10.1016/j.dental.2011.10.014.

[3] Ochandiano S, García-Mato D, Gonzalez-Alvarez A, Moreta-Martinez R, Tousidonis M, Navarro-Cuellar C, Pascau J. Computer-assisted dental implant placement following free flap reconstruction: virtual planning, CAD/CAM templates, dynamic navigation and augmented reality. Frontiers in oncology. 2022;11:754943. https://doi.org/10.3389/fonc.2021.754943.

[4] Etajuri EA, Suliman E, Mahmood WAA, Ibrahim N, Buzayan M, Mohd NR. Deviation of dental implants placed using a novel 3D-printed surgical guide: An in vitro study. Dental and medical problems. 2020;57(4):359-362. https://doi.org/10.17219/dmp/123976.

[5] Nikzad S, Azari A, Ghassemzadeh A. Modified flapless dental implant surgery for planning treatment in a maxilla including sinus lift augmentation through use of virtual surgical planning and a 3-dimensional model. Journal of Oral and Maxillofacial Surgery. 2010;68(9):2291-2298. https://doi.org/10.1016/j.joms.2010.02.002.

[6] Brief J, Edinger D, Hassfeld S, Eggers G. Accuracy of image-guided implantology. Clinical Oral Implants Research. 2005;16(4):495-501. https://doi.org/10.1111/j.1600-0501.2005.01133.x.

[7] Ganeles J. Image guidance for implants. Image. 2013;9(4).

[8] Tordiglione L, De Franco M, Bosetti G. The prosthetic workflow in the digital era. International Journal of Dentistry. 2016(1):9823025.

[9] Surovas A. A digital workflow for modeling of custom dental implants. 3D printing in medicine. 2019;5(1):9.

[10] Hall MA, Karawia I, Mahmoud AZ, Mohamed OS. Knowledge, awareness, and perception of digital dentistry among Egyptian dentists: a cross-sectional study. BMC Oral Health. 2023;23(1):963.

[11] Suganna M, Kausher H, Ali ABMR, Abed MM, Albishi WS, Al Hajji FA, Sultan NA. Knowledge on applications of 3D Design and Printing in Dentistry among Dental practitioners in Saudi Arabia: a questionnaire-based survey. Cureus. 2022;14(8).

[12] Radwan HA, Alsharif AT, Alsharif MT, Aloufi MR, Alshammari BS. Digital technologies in dentistry in Saudi Arabia: Perceptions, practices and challenges. Digital Health. 2023;9:20552076231197095.

[13] Chrcanovic BR, Albrektsson T, Wennerberg A. Bruxism and dental implants: a meta-analysis. Implant dentistry. 2015;24(5):505-516.

[14] Zhou Y, Gao J, Luo L, Wang Y. Does bruxism contribute to dental implant failure? A systematic review and meta-analysis. Clinical implant dentistry and related research. 2016;18(2):410-420.

[15] Chrcanovic BR, Kisch J, Albrektsson T, Wennerberg A. Bruxism and dental implant failures: a multilevel mixed effects parametric survival analysis approach. Journal of oral rehabilitation. 2016;43(11):813-823.

[16] Shujaat S, Bornstein MM, Price JB, Jacobs R. Integration of imaging modalities in digital dental workflows-possibilities, limitations, and potential future developments. Dentomaxillofacial Radiology. 2021;50(7):20210268.

[17] Xing Gao B, Iglesias-Velázquez O, Gf Tresguerres F, Rodríguez González Cortes AF, Tresguerres I, Ortega Aranegui R, Torres J. Accuracy of digital planning in zygomatic implants. International Journal of Implant Dentistry. 2021;*7*:1-8.

[18] Kernen F, Kramer J, Wanner L, Wismeijer D, Nelson K, Flügge, T. A review of virtual planning software for guided implant surgery-data import and visualization, drill guide design and manufacturing. BMC Oral Health. 2020;20(1):251.

[19] Moro SA, Thomé G, Padovan LEM, da Silva RD, Tiossi R, Fontão FNGK. A zygomatic bone study using virtual dental implant planning software. Journal of Oral Implantology. 2022;48(3):171-176.

[20] Joda T, Brägger U. Digital vs. conventional implant prosthetic workflows: a cost/time analysis. Clinical oral implants research. 2015;26(12):1430-1435.

REVISTA CIENTÍFICA - RECIMA21 ISSN 2675-6218

[21] Papaspyridakos P, AlFulaij F, Bokhary A, Sallustio A, Chochlidakis K. Complete digital workflow for prosthesis prototype fabrication with double digital scanning: accuracy of fit assessment. Journal of Prosthodontics. 2023;32(1):49-53. https://doi.org/10.1111/jopr.13492

[22] Gallardo YR, Bohner L, Tortamano P, Pigozzo MN, Lagana DC, Sesma N. Patient outcomes and procedure working time for digital versus conventional impressions: A systematic review. The Journal of prosthetic dentistry. 2018;119(2):214-219. https://doi.org/10.1016/j.prosdent.2017.07.007