REVISTA CIENTÍFICA - RECIMA21 ISSN 2675-6218

GUIDED BIMAXILLARY REHABILITATION WITH REDUCED INTERMAXILLARY PROSTHETIC SPACE: A CASE REPORT

REABILITAÇÃO BIMAXILAR GUIADA COM REDUÇÃO DO ESPAÇO PROTÉTICO INTERMAXILAR: RELATO DE CASO

REHABILITACIÓN BIMAXILAR GUIADA CON REDUCCIÓN DEL ESPACIO PROTÉSICO INTERMAXILAR: REPORTE DE UN CASO

Thiago Tatim[1], Lisandra Lopez Comparing[1], Gizelli de Souza Dall Agnol[1], Roberta Schroder Rocha[2], Rogéria Acedo Vieira[1]

e737320
https://doi.org/10.47820/recima21.v7i3.7320
PUBLISHED: 03/2026

ABSTRACT
Implant-supported prosthesis rehabilitation can be a challenge in cases where there is no space between the arches, requiring an increase in the vertical dimension of occlusion (VDO) through osteotomy to install the prosthesis. This case report describes a 65-year-old patient with a reduced intermaxillary space, in whom virtual-assisted bimaxillary full-arch rehabilitation was performed. To this end, diagnostic and planning methods were employed, including tomography, cephalometric radiographs, photographs, and impressions. Surgical guides were fabricated based on virtual planning. Six Grand Morse Helix Acqua implants were installed in the maxilla, and osteotomy was performed in the mandible, followed by the installation of four Grand Morse Helix Acqua implants (Neodent, Curitiba, Brazil). This case report highlights that bimaxillary rehabilitation is challenging; however, with the implementation of appropriate virtual planning, this challenge can be successfully overcome.

KEYWORDS: Dental Implants. Surgery. Computer-Assisted. Dental Prosthesis. Implant-Supported. Osteotomy. Case Reports.

RESUMO
A reabilitação com próteses implantossuportadas pode ser um desafio nos casos em que não há espaço entre as arcadas dentárias, exigindo um aumento na dimensão vertical de oclusão (DVO) por meio de osteotomia para a instalação da prótese. Este relato de caso tem como objetivo descrever o caso clínico de um paciente de 65 anos com espaço intermaxilar reduzido, no qual foi realizada reabilitação bimaxilar de arco completo assistida virtualmente. Para tanto, foram empregados métodos de diagnóstico e planejamento, como tomografia, radiografias cefalométricas, fotografias e moldagens. Guias cirúrgicos foram confeccionados com base no planejamento virtual. Foram instalados seis implantes Grand Morse Helix Acqua na maxila e realizada osteotomia na mandíbula, seguida da instalação de quatro implantes Grand Morse Helix Acqua (Neodent, Curitiba, Brasil). Este relato de caso evidencia que a reabilitação bimaxilar representa um desafio; entretanto, com a implementação de um planejamento virtual adequado, esse desafio pode ser superado com sucesso.

PALAVRAS-CHAVE: Implantes Dentários. Cirurgia Assistida por Computador. Prótese Dentária Fixada por Implante. Osteotomia. Relatos de Casos.

[1] Department of Implantology, Ilapeo College, Curitiba, Paraná, Brazil.
[2] Independent researcher, Curitiba, Paraná, Brazil.

This article is published in Open Access under the Creative Commons Attribution 4.0 International (CC-BY) license, which allows unrestricted use, distribution and reproduction in any medium, provided the original author and source are credited.

REVISTA CIENTÍFICA - RECIMA21 ISSN 2675-6218

RESUMEN
La rehabilitación con prótesis implantosoportadas puede ser un reto en casos donde el espacio entre las arcadas dentales es insuficiente, requiriendo un aumento en la dimensión vertical de oclusión (VDO) mediante osteotomía para la colocación de la prótesis. Este reporte de caso tiene como objetivo describir el caso clínico de un paciente de 65 años con espacio intermaxilar reducido, en quien se realizó rehabilitación bimaxilar de arcada completa mediante asistencia virtual. Se emplearon métodos de diagnóstico y planificación, incluyendo tomografía computarizada, radiografías cefalométricas, fotografías e impresiones. Se fabricaron guías quirúrgicas con base en la planificación virtual. Se colocaron seis implantes Grand Morse Helix Acqua en el maxilar superior y se realizó osteotomía en la mandíbula, seguida de la colocación de cuatro implantes Grand Morse Helix Acqua (Neodent, Curitiba, Brasil). Este reporte de caso destaca que la rehabilitación bimaxilar representa un desafío; sin embargo, con la implementación de una planificación virtual adecuada, este desafío puede ser superado con éxito.

PALABRAS CLAVE: Implantes dentales. Cirugía asistida por computador. Prótesis Dental de Soporte Implantado. Osteotomía. Informes de Casos.

INTRODUCTION

Implant-supported prosthetic rehabilitation presents a challenge in adequately reconstructing aesthetics and functionality[1,2]. These challenges are related to bone quality, the availability of bone tissue, and the severity of bone resorption in the anteroposterior and transverse directions. In some cases, there is no space between the arches, requiring an increase in the vertical dimension of occlusion (VDO) through osteotomy to install the prosthesis[3].

One option that makes rehabilitation more predictable is the use of guided surgeries. Guided surgery was introduced in the late 1990s, and due to technological advancements, its use has increased. It allows implants to be inserted predictably and safely after a digital analysis of the alveolar bone[4]. This approach has become an ally in needing osteotomy to obtain more prosthetic space[5–7].

This case report presents a guided-surgery bimaxillary rehabilitation case in a patient with reduced VDO.

CASE REPORT

A 65-year-old male patient with no systemic changes and total upper and lower edentulous presented to the clinic for bimaxillary rehabilitation. The patient reported that three years ago he underwent extraction of all his teeth and that, during this period, he did not use upper or lower dentures. The primary patient´s complaint was difficulty in speaking and chewing. Written informed consent was obtained from the patient before treatment.

For treatment planning, an intraoral clinical examination, photographic recording, study models, and tomographic examination were performed (Figure 1).

This article is published in Open Access under the Creative Commons Attribution 4.0 International (CC-BY) license, which allows unrestricted use, distribution and reproduction in any medium, provided the original author and source are credited.

REVISTA CIENTÍFICA - RECIMA21 ISSN 2675-6218



Figure 1. (A) Frontal extraoral view. (B) Intraoral view. (C) Patient's smile line.

The virtual treatment plan was performed in CoDiagnostiX (Dental Wings GmbH, Chemnitz, Germany) using NeoGuide Surgery (NGS) (Neodent, Curitiba, Brazil). Six implants were planned in the maxilla and four in the mandible. Upper and lower implant-supported full-arch acrylic resin prostheses were proposed.

A multifunctional and tomographic guide was manufactured. With the aid of the multifunctional guide, the vertical dimension of occlusion (VDO) was verified, and a lack of bone availability, mainly in the anterior region of the mandible, was observed (Figure 2). An osteotomy of the alveolar process was indicated to obtain intermaxillary space to adjust the VDO.

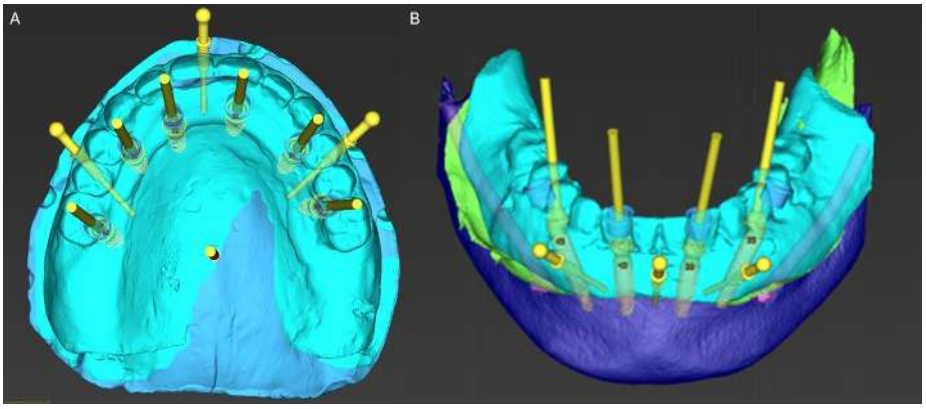

Figure 2. (A) Multifunctional and tomographic guide for (A) maxilla and (B) mandible. (C) Check the VDO using the multifunctional guide.

ISSN: 2675-6218 - RECIMA21
This article is published in Open Access under the Creative Commons Attribution 4.0 International (CC-BY) license, which allows unrestricted use, distribution and reproduction in any medium, provided the original author and source are credited.

REVISTA CIENTÍFICA - RECIMA21 ISSN 2675-6218

Teleradiography was used to determine the extent of osteotomy to be performed. A plane was drawn from the labial-mental groove in the insertion of the buccal muscle, and a 7.4 mm measurement was defined, which posteriorly coincided with the clinical measurement (Figure 3).

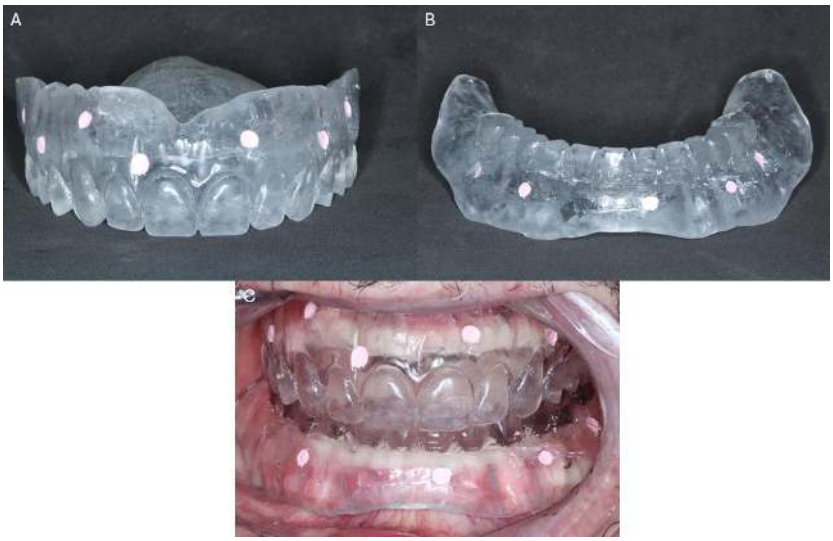

Figure 3. Teleradiography showing the plane drawn and the measurements.

The patient underwent the surgical procedure under local anesthesia, with blockade of the posterior, anterior, and middle superior alveolar nerves. Infiltrative anesthesia of the nasopalatine and greater palatine nerves was performed in the palate with mepivacaine HCL 2% with epinephrine 1/100,000. The surgical guide was well adapted to the maxilla and fixed with a screw in the palate and three pins in the vestibular region of the ridge to improve stability. Six Grand Morse Helix Acqua implants were installed in the maxilla (Neodent, Curitiba, Brazil): one 4.3x13 mm implant in region 16 (insertion torque of 45 N), one 3.5x13 mm implant in region 14 (insertion torque of 60 N), one 3.5 x 11.5 mm implant in region 12 (insertion torque of 50 N), one 4.0 x 13 mm implant in region 22 (insertion torque of 40 N), one 3.75 x 13 mm implant in region 24 (insertion torque of 60 N), and one 3.5 x 11.5 mm implant in region 26 (insertion torque of 45 N). One GM Mini Conical Abutment 2.5mm, two GM Mini Conical Abutment 3.5, two GM Mini Conical Abutment 5.5, and one GM Mini Conical Abutment 5.5 mm (Neodent, Curitiba, Brazil) were installed. The implants were placed without opening a flap, in accordance with the previous plan and the NGS manufacturer's recommendations. The surgical procedure was finished without complications.

For mandible surgery, bilateral inferior alveolar nerve block and infiltration anesthesia were performed in the anteroinferior region. After adaptation of the surgical guide, the implant entry regions were marked with gentian violet to visualize potential damage to the inserted gingiva (Figure 4A). Then, a supracrestal incision was made with two posterior oblique incisions to relax

ISSN: 2675-6218 - RECIMA21
This article is published in Open Access under the Creative Commons Attribution 4.0 International (CC-BY) license, which allows unrestricted use, distribution and reproduction in any medium, provided the original author and source are credited.

REVISTA CIENTÍFICA - RECIMA21 ISSN 2675-6218

and preserve the inserted gingiva (Figure 4B). The surgical guide was adapted again, and the first drilling was performed using a 2.0 drill to mark the implant site prior to osteotomy (Figure 4C). The multifunctional guide was adapted to mark the osteotomy height (7.49 mm), as previously defined by teleradiography and the multifunctional guide (Figures 4C and 4D). After removing the multifunctional guide, the osteotomy was performed with the aid of the CVDentus piezoelectric (CVDentus, São Jose dos Campos, Brazil) (Figure 5).

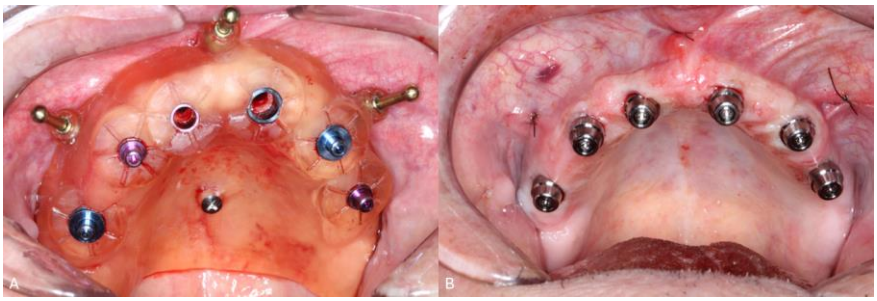

Figure 4. (A) Markings with gentian violet in the implant entry regions. (B) First milling performed with the 2.0 drill to mark the implant site before the osteotomy. (C) Adaptation of the multifunctional guide to confirm the osteotomy height. (D) Marking of the osteotomy height (7.49 mm) previously defined by teleradiography.

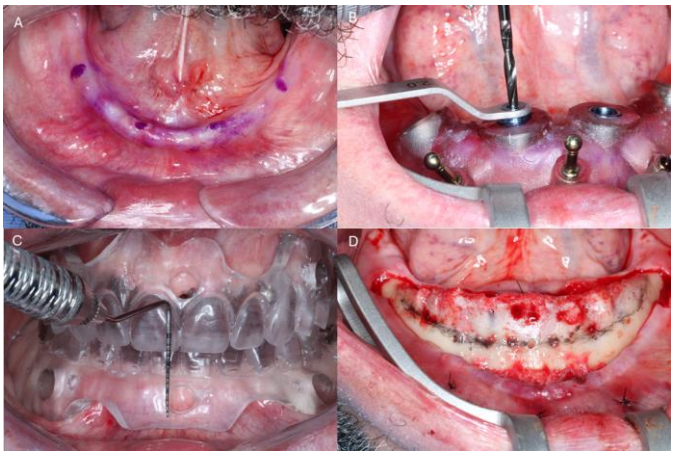

Figure 5. Osteotomy process with the aid of an electric piezo before the implant placement in the mandible.

After osteotomy and regularization of the ridge, four Grand Morse Helix Acqua (Neodent, Curitiba, Brazil) implants were placed according to the manufacturer's drilling recommendations, one 3.75 x 10 mm implant in region 33 (insertion torque of 60 N.cm), one 3.75 x 10 mm implant in region 35 (insertion torque of 35 N.cm), one 3.75 x 11.5 mm implant in region 45 (insertion torque of 60 N.cm) and one 3.75 x 10 mm implant in region 43 (insertion torque of 60 N.cm). Two GM Mini Conical Abutments of 1.5 mm, one Angled 17 GM Mini Conical Abutment of 1.5mm, and one Angled 17 GM Mini Conical Abutment of 2.5mm (Neodent, Curitiba, Brazil) were installed.

ISSN: 2675-6218 - RECIMA21
This article is published in Open Access under the Creative Commons Attribution 4.0 International (CC-BY) license, which allows unrestricted use, distribution and reproduction in any medium, provided the original author and source are credited.

Immediately after surgery, a transfer mold was taken using a bimaxillary multifunctional guide; the teeth were tested. With approval, the definitive prosthesis was installed in the mandible 15 days after surgery and in the maxilla 60 days after surgery (Figure 6A and B). Following prosthesis installation, a panoramic X-ray was obtained (Figure 6C), and the patient was monitored every 3 months for 1 year. No biological or mechanical complications occurred during the follow-up period.

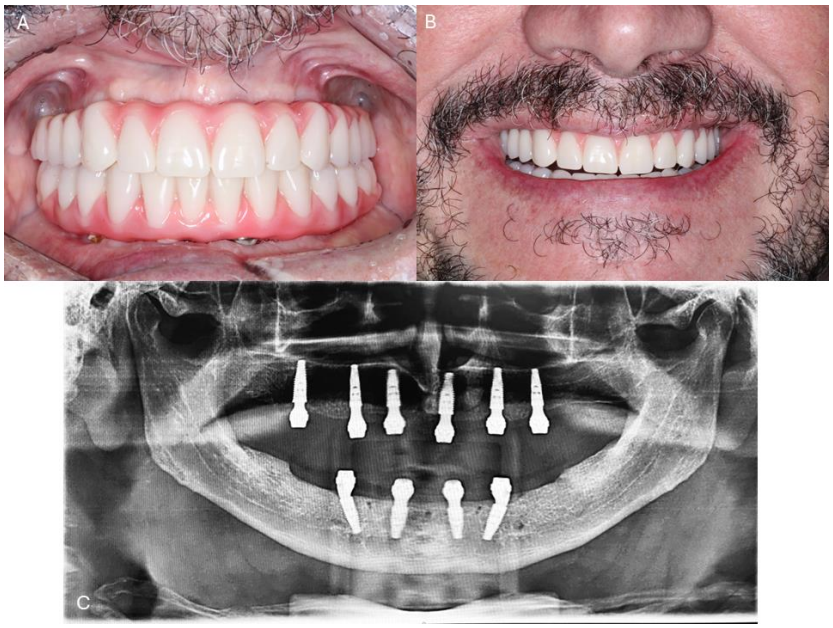

Figure 6. (A) Definitive prostheses installed; (B) Final smile appearance after installation of the definitive prostheses. (C) Panoramic X-ray taken after prostheses installation.

DISCUSSION

Bimaxillary full-arch rehabilitation with fixed prostheses is often associated with bone reduction procedures[8]. Bone leveling of the alveolar socket create a more favorable alveolar plane, potentially facilitating the surgical and prosthetic planning, including determining optimal sites for implant placement[7,8].

The use of a clear acrylic reduction guide may help ensure adequate restorative space for the prosthetic components and titanium bar[7,9]. The reduction guide improves implant placement in areas with mature bone, thereby increasing the likelihood of manufacturing a prosthesis that can be effectively cleaned and sanitized. With adequate prosthetic space, acrylic resin can be used in the quantity indicated by the manufacturer which may reduce the risk of prosthesis fractures and tooth loosening[6,10,11].

Insufficient interarch space represents a challenging clinical situation and may complicate both surgical and prosthetic phases[12,13]. Assertive results can be optimized with pre-surgical

This article is published in Open Access under the Creative Commons Attribution 4.0 International (CC-BY) license, which allows unrestricted use, distribution and reproduction in any medium, provided the original author and source are credited.

diagnosis and planning[14]. In this reported case, an osteotomy of the mandible was performed to create a better site for implant placement in mature bone with adequate prosthesis thickness. This approach was intended to allow the fabrication of a prosthetic base with sufficient surface area for cleaning, potentially contributing to the health of the periodontium and adjacent gums.

An increase in vertical dimension of occlusion (VDO) may be considered to achieve specific functional and esthetic objectives, such as correcting anterior tooth relationships, improving maxillary lip position, and providing greater interocclusal space for restorative materials [15]. After the VDO increases, the stomatognathic system rapidly adapts. The safer value to increase the VDO is 5 mm; however, an increase of more than 5 mm is not dangerous. Increased VDO associated with fixed prostheses is also associated with less severe symptoms [15]. In this case report, we performed a VDO increase higher than 5 mm associated with a fixed prosthesis, and no symptoms were observed after one year of follow-up.

Ostectomy may be performed using freehand or guided approaches to increase intermaxillaty space[16,17]. However, CAD/CAM-generated surgical guides often prevent complications such as under-reduction or reduction of the alveolar ridge higher than necessary[18,19]. In this case, an acrylic guide was used to aid in bone reduction and transfer the osteotomy measurement defined using teleradiography[20].

The piezoelectric was used for osteotomy based on reports suggesting it provides safer surgery with less tissue aggression, reduced bone repair time, and reduced bleeding. It optimizes precision in the selectivity of cutting hard tissues, reduces the possibility of necrosis, minimizes the risk of injuries to soft tissues, including vessels and nerves, and improves the patient's intraoperative comfort[21,22]. In opposition, rotary instruments have been associated with increased tissue temperature, causing cell death, possible injuries to soft tissues, and longer tissue repair time[23].

Changing the interocclusal space is complex clinical decision that relies on the clinician's evaluation, taking into account facial and dental esthetics. In our case, a new technique was used to plan the osteotomy performed before the surgery. Teleradiography, used to draw a plane from the labial-mental groove at the insertion of the buccal muscle, appeared to provide a clinically acceptable estimation of posterior bone reduction, as confirmed intraoperatively. However, further studies are necessary to determine the reproducibility and broader applicability of this planning approach.

CONCLUSION

Bimaxillary rehabilitation is a challenge that virtual planning can minimize. Mandibular alveolar ridge osteotomy is indicated when insufficient prosthetic space is identified and can be performed safely and predictably.

This article is published in Open Access under the Creative Commons Attribution 4.0 International (CC-BY) license, which allows unrestricted use, distribution and reproduction in any medium, provided the original author and source are credited.

REVISTA CIENTÍFICA - RECIMA21 ISSN 2675-6218

REFERENCES

[1] Adell R, Lekholm U, Rockler B, Brånemark P-I. A 15-year study of osseointegrated implants in the treatment of the edentulous jaw. Int J Oral Surg. 1981;10:387–416.

[2] Douley J, Boisramé S, Guiol J. Complete-arch implant-supported dental rehabilitations assisted by navigated surgery: a satisfaction study. Journal of Oral Medicine and Oral Surgery. 2025;31:18. https://doi.org/10.1051/mbcb/2025010.

[3] Yadfout A, El Aoud J, Merzouk N, Slaoui Hasnaoui J. Increasing Vertical Dimension of Occlusion (VDO): Review. Clin Cosmet Investig Dent. 2024;16:135–42. https://doi.org/10.2147/CCIDE.S453704.

[4] Markiewicz M, Nowicki A. Accuracy of Computer-Guided Dental Implant Placement: A Clinical Comparison of Three Surgical Guide Types. J Clin Med 2025;14:8652. https://doi.org/10.3390/jcm14248652.

[5] Johansson B, Friberg B, Nilson H. Digitally planned, immediately loaded dental implants with prefabricated prostheses in the reconstruction of edentulous maxillae: a 1-year prospective, multicenter study. Clin Implant Dent Relat Res 2009;11:194–200.

[6] Papaspyridakos P, Chen C-J, Chuang S-K, Weber H-P, Gallucci GO. A systematic review of biologic and technical complications with fixed implant rehabilitations for edentulous patients. International Journal of Oral & Maxillofacial Implants. 2012;27.

[7] Rubino L, Grande F, Catapano S, Ganz S, Mijiritsky E. Bone reduction with stackable surgical guides: an evolving digital workflow. Digital Dentistry Journal. 2026;3:100062. https://doi.org/10.1016/j.ddj.2025.100062.

[8] Bell WH, Buche WA, Kennedy JW, Ampil JP. Surgical correction of the atrophic alveolar ridge: A preliminary report on a new concept of treatment. Oral Surgery, Oral Medicine, Oral Pathology. 1977;43:485–98.

[9] Moraschini V, Poubel LA da C, Ferreira VF, dos Sp Barboza E. Evaluation of survival and success rates of dental implants reported in longitudinal studies with a follow-up period of at least 10 years: a systematic review. Int J Oral Maxillofac Surg. 2015;44:377–88.

[10] Ventura J, Jiménez-Castellanos E, Romero J, Enrile F. Tooth fractures in fixed full-arch implant-supported acrylic resin prostheses: a retrospective clinical study. Int J Prosthodont. 2016;29:161–5.

[11] Wittcinski C, Kubo FM, Teixeira ML, Pelegrine AA. Complications in implant-supported full-arch immediate prostheses: a Brazilian retrospective, observational, longitudinal study. Acta Odontológica Latinoamericana. 2025;38:76–81. https://doi.org/10.54589/aol.38/1/76.

[12] Engstrand P, Grondahl K, Öhrnell L, Nilsson P, Nannmark U, Branemark P. Prospective follow-up study of 95 patients with edentulous mandibles treated according to the Branemark Novum concept. Clin Implant Dent Relat Res. 2003;5:3–10.

[13] Krennmair S, Weinländer M, Malek M, Forstner T, Krennmair G, Stimmelmayr M. Mandibular full-arch fixed prostheses supported on 4 implants with either axial or tilted distal implants: A 3-year prospective study. Clin Implant Dent Relat Res. 2016;18:1119–33.

This article is published in Open Access under the Creative Commons Attribution 4.0 International (CC-BY) license, which allows unrestricted use, distribution and reproduction in any medium, provided the original author and source are credited.

[14] Auduc C, Douillard T, Nicolas E, El Osta N. Fully Digital Workflow in Full-Arch Implant Rehabilitation: A Descriptive Methodological Review. Prosthesis. 2025;7:85. https://doi.org/10.3390/prosthesis7040085.

[15] Yadfout A, El Aoud J, Merzouk N, Slaoui Hasnaoui J. Increasing Vertical Dimension of Occlusion (VDO). Clin Cosmet Investig Dent. 2024:135–42.

[16] Friberg B, Henningsson C, Jemt T. Rehabilitation of edentulous mandibles by means of turned Brånemark System® implants after one-stage surgery: a 1-year retrospective study of 152 patients. Clin Implant Dent Relat Res. 2005;7:1–9.

[17] Colomina LE. Immediate loading of implant-fixed mandibular prostheses: a prospective 18-month follow-up clinical study—preliminary report. Implant Dent. 2001;10:23–9.

[18] Katsoulis J, Pazera P, Mericske-Stern R. Prosthetically driven, computer-guided implant planning for the edentulous maxilla: a model study. Clin Implant Dent Relat Res. 2009;11:238–45.

[19] Salama MA, Pozzi A, Clark WA, Tadros M, Hansson L, Adar P. The “scalloped guide”: a proof-of-concept technique for a digitally streamlined, pink-free full-arch implant protocol. Int J Periodontics Restorative Dent. 2018;38:791–8.

[20] Jensen OT, Adams MW, Cottam JR, Parel SM, Phillips III WR. The All-on-4 shelf: maxilla. Journal of Oral and Maxillofacial Surgery. 2010;68:2520–7.

[21] Fiorillo L, Puleio F, Nucera R, Lo Giudice R, Lo Giudice G. Optimizing Osteotomy Techniques: Comparison of Conventional Rotary Instruments Versus Other Bone Cutting Devices. Journal of Craniofacial Surgery. 2025;36:1320–4. https://doi.org/10.1097/SCS.0000000000010951.

[22] Mancini A, Inchingolo AM, Chirico F, Colella G, Piras F, Colonna V, et al. Piezosurgery in Third Molar Extractions: A Systematic Review. J Pers Med. 2024;14:1158. https://doi.org/10.3390/jpm14121158.

[23] Grecchi F, Zollino I, Parafioriti A, Mineo G, Pricolo A, Carinci F. One-step oral rehabilitation by means of implants’ insertion, Le Fort I, grafts, and immediate loading. Journal of Craniofacial Surgery. 2009;20:2205–10.

This article is published in Open Access under the Creative Commons Attribution 4.0 International (CC-BY) license, which allows unrestricted use, distribution and reproduction in any medium, provided the original author and source are credited.