REVISTA CIENTÍFICA - RECIMA21 ISSN 2675-6218

INFLUENCE OF OZONE THERAPY ON MONONUCLEAR INFILTRATE AND MAST CELLS IN TISSUE REPAIR – IN VIVO PILOT STUDY

INFLUÊNCIA DA TERAPIA COM OZÔNIO SOBRE INFILTRADO MONONUCLEAR E NOS MASTÓCITOS NO REPARO TECIDUAL – ESTUDO PILOTO IN VIVO

INFLUENCIA DE LA OZONOTERAPIA SOBRE EL INFILTRADO MONONUCLEAR Y LOS MASTOCITOS EN LA REPARACIÓN DE TEJIDOS: ESTUDIO PILOTO IN VIVO

Sarah Souza Lima Nery Dantas[1], Bruna Carvalho Lopez Moreno[2], Carla Barreto Cerqueira[3], Antônio Márcio Marchionni[4], Flavia Quadros Lima[5], Alena Ribeiro Alves Peixoto Medrado[6]

e737450
https://doi.org/10.47820/recima21.v7i3.7450

PUBLISHED: 03/2026

ABSTRACT

Objective: To evaluate the effect of ozone gas and ozonized oil on mononuclear infiltrate and mast cell numbers in a standard experimental skin wound healing model. Methods: Thirty Wistar rats received a standardized skin wound and were assigned to three groups: control (CG), ozone gas insufflation (OGG), and topical sunflower ozonized oil (OOG). Euthanasia occurred on days 5 and 10. Histological sections were stained with Hematoxylin-eosin and toluidine blue for quantitative and semi-quantitative analyses. ANOVA followed by Student's t-test was applied ($p<0.05$). Results: No significant differences were observed in mononuclear infiltrate among groups at either time point ($p>0.05$). Mast cell counts, however, were significantly higher in ozone-treated groups, particularly degranulated mast cells on day 5 (OGG $p=0.0003$; OOG $p=0.004$) compared to controls. Conclusion: Ozone therapy did not significantly modulate mononuclear infiltrate but increased mast cell numbers during early wound healing, regardless of administration route.

KEYWORDS: Wound Healing. Ozone Therapy. Inflammatory Infiltrate. Mast Cell.

RESUMO

Objetivo: Avaliar o efeito do gás ozônio e do óleo ozonizado sobre o infiltrado mononuclear e o número de mastócitos em um modelo experimental padrão de cicatrização de feridas cutâneas. Métodos: Trinta ratos Wistar foram submetidos a uma ferida cutânea padronizada e divididos em três grupos: controle (GC), insuflação com gás ozônio (GGO) e aplicação tópica de óleo de girassol ozonizado (GOO). A eutanásia foi realizada nos dias 5 e 10. As amostras foram coradas com hematoxilina-eosina e azul de toluidina para análises quantitativas e semiquantitativas. Os dados foram avaliados por ANOVA seguida do teste t de Student ($p < 0,05$). Resultados: Não foram observadas diferenças significativas no infiltrado mononuclear entre os grupos em nenhum dos períodos avaliados ($p>0,05$). No entanto, a contagem de mastócitos foi significativamente maior nos

[1] Master's degree from the Graduate Program in Interactive Processes of Organs and Systems, Institute of Health Sciences, Federal University of Bahia, Salvador, Bahia, Brazil.
[2] Bachelor's degree in Dentistry, Bahiana School of Medicine and Public Health, Salvador, Bahia, Brazil.
[3] Master's degree in Biotechnology, Graduate Program in Biotechnology, Institute of Health Sciences, Federal University of Bahia, Salvador, Bahia, Brazil.
[4] PhD in Photobiomodulation, Dentistry Program, Bahiana School of Medicine and Public Health, Salvador, Bahia, Brazil.
[5] Dentist; Master's degree in Medicine and Human Health, Bahiana School of Medicine and Public Health.
[6] Associate Professor IV, Department of Biointeraction, Institute of Health Sciences; PhD in Human Pathology from FIOCRUZ/UFBA, Federal University of Bahia, Salvador, Bahia, Brazil.

This article is published in Open Access under the Creative Commons Attribution 4.0 International (CC-BY) license, which allows unrestricted use, distribution and reproduction in any medium, provided the original author and source are credited.

grupos tratados com ozônio, especialmente de mastócitos desgranulados no dia 5 (GGO p=0,0003; GOO p=0,004) em comparação ao grupo controle. Conclusão: A ozonioterapia não modulou significativamente o infiltrado mononuclear, mas aumentou o número de mastócitos na fase inicial da cicatrização, independentemente da via de administração.

PALAVRAS-CHAVE: Reparo tecidual. Ozonioterapia. Infiltrado Inflamatório. Mastócito.

RESUMEN
Objetivo: Evaluar el efecto del gas ozono y el aceite ozonizado sobre el infiltrado mononuclear y el recuento de mastocitos en un modelo experimental estándar de cicatrización de heridas cutáneas. Métodos: Treinta ratas Wistar se sometieron a un tratamiento estandarizado de heridas cutáneas y se dividieron en tres grupos: control (GC), insuflación de ozono (GGO) y aplicación tópica de aceite de girasol ozonizado (GOO). La eutanasia se realizó los días 5 y 10. Las muestras se tiñeron con hematoxilina-eosina y azul de toluidina para análisis cuantitativos y semicuantitativos. Los datos se evaluaron mediante ANOVA seguido de la prueba t de Student ($p < 0,05$). Resultados: No se observaron diferencias significativas en el infiltrado mononuclear entre los grupos en ninguno de los períodos evaluados ($p > 0,05$). Sin embargo, los recuentos de mastocitos fueron significativamente mayores en los grupos tratados con ozono, especialmente en los mastocitos degranulados en el día 5 (GGO $p = 0,0003$; GOO $p = 0,004$) en comparación con el grupo control. Conclusión: La ozonoterapia no moduló significativamente el infiltrado mononuclear, pero sí aumentó el número de mastocitos en la fase temprana de la cicatrización de la herida, independientemente de la vía de administración.

PALABRAS CLAVE: Reparación de tejidos. Ozonoterapia. Infiltrado inflamatório. Mastocitos.

INTRODUCTION

Globally, the prevalence of genetic disorders and chronic non-communicable diseases is increasing, many of which interfere with the biological mechanisms underlying tissue repair. These clinical conditions can disrupt key biochemical pathways, leading to delayed wound healing and the development of chronic wounds. Such complications prolong outpatient and hospital care, increase expenditures on medications and dressings, and ultimately impose a significant burden on public health systems. Within this context, biomodulatory therapies have emerged as promising strategies to enhance tissue repair (Gonzalez *et al*. 2016).

The reparative potential of biomodulatory therapies has been extensively documented, demonstrating benefits across a range of wound types. Among these modalities, laser and LED photobiomodulation, plasma jet therapy, and ozone therapy are particularly notable. The medicinal use of ozone has been reported since the 19th century, with an initial emphasis on its antimicrobial properties (Ebrahimi, 2021). Owing to its highly unstable triatomic structure (O_3), ozone rapidly decomposes, releasing molecular oxygen (O_2) and a free oxygen atom. This process not only enhances local oxygen availability but also promotes molecular reactions that stimulate the biosynthesis of reactive oxygen species (ROS) (Bacci *et al*., 2016). Consequently, ozone can induce a transient, moderate, and controlled oxidative stress response, depending on the administered dosage (Viebahn-Haensler *et al.,* 2024). Through its interactions with various biological constituents,

This article is published in Open Access under the Creative Commons Attribution 4.0 International (CC-BY) license, which allows unrestricted use, distribution and reproduction in any medium, provided the original author and source are credited.

including endothelial cells, erythrocytes, mast cells (MCs), and leukocytes, ozone has been recognized as an adjuvant that modulates the tissue repair process (Liu *et al*., 2022).

Recent studies have highlighted the multifaceted roles of MCs and leukocytes during wound healing. These cells undergo degranulation during the early inflammatory phase and participate in angiogenesis, collagen biosynthesis, and the migration of fibroblasts and keratinocytes, processes crucial to the proliferative and remodeling phases of repair (Dong *et al*., 2020). However, there remains a paucity of evidence regarding the effects of ozone therapy on specific repair parameters, particularly on mononuclear leukocyte infiltration and mast cell dynamics. To date, no studies have elucidated the potential influence of ozone, whether in gaseous form or combined with a vehicle such as oil, on mast cell degranulation or on the modulation of mononuclear inflammatory infiltrates during tissue repair.

Accordingly, the present experimental study aimed to perform a semi-quantitative and histomorphometric analysis of mononuclear inflammatory infiltrates and mast cells at two time points during the proliferative phase of cutaneous repair in rats treated with two distinct modalities of ozone therapy.

1. METODOLOGY

Study Design and Ethical Approval

This experimental study was conducted at the Laboratory of the Adventist College of Bahia (FADBA), Cachoeira, Bahia, Brazil. All procedures were performed in accordance with national and institutional guidelines for the care and use of laboratory animals and were approved by the Ethics Committee on the Use of Animals (CEUA–FADBA) under protocol number CIAEP 01.0039.2013.

Experimental Groups

Thirty male Wistar rats (Rattus norvegicus albinus), weighing approximately 200 g, were used. The animals were randomly assigned to three experimental groups (n = 10 per group): Control Group (CG): treated with 0.9% sterile saline solution; Ozone Gas Group (OGG): treated with gaseous ozone insufflated around the wound margins; Ozonized Oil Group (OOG): treated topically with ozonized sunflower oil. Five animals from each group were euthanized on postoperative days 5 and 10, corresponding to key stages of the proliferative phase of wound repair.

Animal Housing and Husbandry

Throughout the experiment, the rats were maintained under standard sanitary conditions in a conventional animal facility. Each animal was housed in an individual labeled cage containing wood shavings as bedding. Environmental conditions were controlled at 22–25°C, 50–52% relative

This article is published in Open Access under the Creative Commons Attribution 4.0 International (CC-BY) license, which allows unrestricted use, distribution and reproduction in any medium, provided the original author and source are credited.

humidity, and a 12-hour light–dark cycle. All animals received Nuvilab® balanced feed (Suprilab, Brazil) and water ad libitum.

Surgical Procedure

Following the recommendations of Damy *et al.,* (2010), animals were weighed and anesthetized with ketamine hydrochloride 10% (Dopalen®, São Paulo, Brazil; 75 mg/mL) and xylazine hydrochloride 2% (Anasedan®, São Paulo, Brazil; 5 mg/mL) at doses of 2 mg/kg and 3 mg/kg, respectively. The dorsal region was then shaved and disinfected with 10% povidone-iodine solution.

A standardized full-thickness excisional wound was created in the mid-dorsal region using a 6 mm circular biopsy punch (Stiefel®, Germany), according to the model described by Medrado *et al.,* (2003). All procedures were performed by a single calibrated operator. Control group animals underwent the same surgical protocol but did not receive ozone treatment.

Ozone Therapy Protocols

In the Ozone Gas Group (OGG), treatment was performed using a Philozon® ozone generator (Philozon Indústria e Comércio de Geradores de Ozônio LTDA, Santa Catarina, Brazil). Medical-grade oxygen was converted to ozone at a concentration of 13 µg/mL and a constant flow rate of 1 L/min. The ozone–oxygen mixture was collected in a 4 mL syringe and insufflated subcutaneously at four equidistant points around the wound margin (1 mL total), using an insulin needle. This procedure was repeated once daily for three consecutive days after surgery.

In the Ozonized Oil Group (OOG), 100% ozonized sunflower oil (Philozon®, Brazil) was applied topically. Using a pipette, 0.05 mL of ozonized oil was evenly distributed over the wound surface, fully covering the lesion. Treatments were administered once daily for three consecutive postoperative days.

Tissue Collection and Histological Processing

Following deep sedation, the animals were placed in euthanasia chambers where carbon dioxide gas was released at a concentration of 5 L/min until death was confirmed. After confirmation, a full-thickness tissue sample containing the surgical wound was excised from the dorsal region. The specimens were fixed in 10% neutral-buffered formalin for at least 48 hours.

Skin fragments containing the lesion were sectioned into 4 µm-thick slices and stained with hematoxylin and eosin (H&E) for evaluation of the mononuclear inflammatory infiltrate, and with toluidine blue for the identification and quantification of mast cells.

This article is published in Open Access under the Creative Commons Attribution 4.0 International (CC-BY) license, which allows unrestricted use, distribution and reproduction in any medium, provided the original author and source are credited.

Image acquisition of the stained histological sections was performed using Motic Images Advanced 3.0® software (Motic China Group Co. Ltd.) at the Laboratory of Oral Biochemistry, Institute of Health Sciences, Federal University of Bahia. A standardized analysis area (100 μm²) was defined for all samples, encompassing the central region of the wound and extending laterally to the adjacent normal tissue. Five representative images per specimen were captured at the predetermined dimensions and used for both quantitative and semi-quantitative analyses.

For sections stained with H&E, images were captured at 100× magnification; for those stained with toluidine blue, at 400× magnification. All micrographs were saved as JPEGs. Analyses were performed and documented by a single calibrated examiner with extensive experience in histological evaluation.

In H&E-stained sections, the degree of inflammation was assessed according to criteria adapted from Alvarenga *et al.,* (2020). A semi-quantitative analysis of the mononuclear inflammatory infiltrate was conducted, categorized as absent (0), mild (+), moderate (++), intense (+++), or very intense (++++). The grading criteria were defined as follows: Very intense (++++): variable present in >75% of the analyzed area; Intense: 50–75%; Moderate: 25–50%; Mild: ≤25%.

In toluidine blue–stained sections, mast cell quantification considered both intact mast cells (with preserved morphology) and degranulated mast cells (identified by the presence of extracellular metachromatic granules).

Statistical Analysis

A descriptive dataset was organized in Microsoft Excel (Windows 10) to obtain median and quartile values. The Shapiro–Wilk test was applied to assess data normality. Analysis of variance (ANOVA) was subsequently performed, followed by the Student's t-test to determine statistically significant differences between groups. The level of significance was set at $p < 0.05$.

2. RESULTS

At postoperative day 5, the Control Group (CG) exhibited an intense mononuclear inflammatory infiltrate in the wound area, which further increased by day 10 ($p = 0.008$). In contrast, both the Ozone Gas Group (OGG) and the Ozonized Oil Group (OOG) demonstrated moderate levels of mononuclear infiltrate on day 5, with no significant differences between them ($p > 0.05$) (Figure 1A, C, E). By day 10, OGG maintained a moderate infiltrate compared with CG and OOG;

This article is published in Open Access under the Creative Commons Attribution 4.0 International (CC-BY) license, which allows unrestricted use, distribution and reproduction in any medium, provided the original author and source are credited.

however, intergroup differences were not statistically significant at this time point (Table 1; Figure 1B, D, F).

Within-group comparisons revealed an overall increase in the total number of mast cells from day 5 to day 10 across all experimental groups. In the CG, this rise was mainly attributed to a significant increase in degranulated mast cells ($p = 0.006$), while the number of intact mast cells showed a decreasing trend ($p > 0.05$). Similarly, OGG demonstrated a significant increase in degranulated mast cells over time ($p = 0.04$). In OOG, total, intact, and degranulated mast cell counts also increased between days 5 and 10, although these changes were not statistically significant ($p > 0.05$) (Table 2).

On day 5, both OGG and OOG exhibited higher total mast cell counts than CG, though the difference was not statistically significant ($p > 0.05$). A significant difference was observed only in the number of degranulated mast cells, which was markedly higher in OGG and OOG compared with CG ($p = 0.0003$ and $p = 0.004$, respectively) (Table 3; Figure 2A, C, E).

By postoperative day 10, the overall pattern remained consistent: both ozone-treated groups showed higher total mast cell counts relative to CG, but without statistically significant differences ($p > 0.05$) (Tables 2 and 3; Figures 2B, D, F; Graphs 1 and 2).

Table 1. Medians and interquartile ranges for mononuclear inflammatory infiltrate in the study groups. Hematoxylin-eosin, 100X

Variables		CG		OGG		OOG	
		5º dia Med (q1-q3)	10º dia Med (q1-q3)	5º dia Med (q1-q3)	10º dia Med (q1-q3)	5º dia Med (q1-q3)	10º dia Med (q1-q3)
Mononuclear inflammatory infiltrate		3(2,5-3)	4(4-4)	3(3-3)	3(3-3,5)	3(3-3)	4(3,5-4)
	p-value	0,008*		0,690		0,063	

*Student's t-test.

This article is published in Open Access under the Creative Commons Attribution 4.0 International (CC-BY) license, which allows unrestricted use, distribution and reproduction in any medium, provided the original author and source are credited.

REVISTA CIENTÍFICA - RECIMA21 ISSN 2675-6218

Table 2. Medians and interquartile ranges of the quantity of intact and degranulated mast cells in the different experimental groups. Toluidine Blue, 100X

Grup	Day 5		Day 10	
	Intact	Degranulated	Intact	Degranulated
CG	12 (10-14)	4 (4-4)	13 (12-14)	8 (8-9)
OGG	13 (12-14)	8 (8-9)	14 (14-17)	10 (10-14)
OOG	15 (9-15)	10 (10-14)	20 (10-22)	20 (10-22)

Descriptive statistics, Median, and interquartile ranges.

Table 3. Record of inter- and intra-group statistical analysis on days 5 and 10 of the postoperative period

Groups	Intact Mast cells	Degranulated Mast cells
CG Day 5 X OGG Day 5	0,28	0,0003*
CG Day 5 X OOG Day 5	0,39	0,004*
CG Day 5 X CG Day 10	0,25	0,006*
CG 10º dia X OGG 10º dia	0,10	0,21
CG 10º dia X OOG Day 10	0,23	0,07
OOG Day 5 X OGG Day 10	0,46	0,04*
OOG Day 5 X OOG Day 10	0,27	0,14

*p<0.05. T-test.

ISSN: 2675-6218 - RECIMA21
This article is published in Open Access under the Creative Commons Attribution 4.0 International (CC-BY) license, which allows unrestricted use, distribution and reproduction in any medium, provided the original author and source are credited.

REVISTA CIENTÍFICA - RECIMA21 ISSN 2675-6218

Figure 1. (A) Quantity of intact and degranulated mast cells in the different experimental groups on day 5; (B) Quantity of intact and degranulated mast cells in the different experimental groups on day 10. Toluidine Blue, 100X

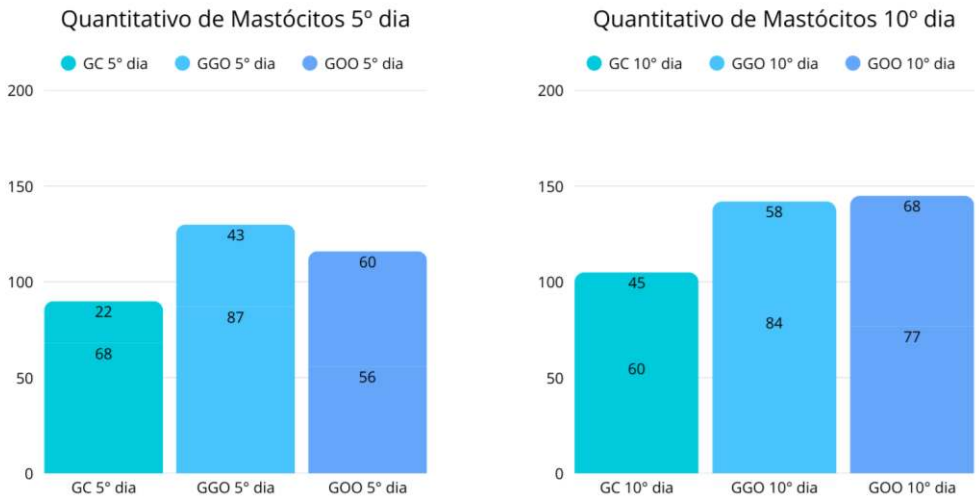

Figure 2. Histomorphometric analysis of the experimental groups. Photomicrographs of histological skin sections from Wistar rats showing the standardized cutaneous wound at 5 and 10 postoperative days. Mononuclear inflammatory infiltrates are observed across all groups. On day 5, the Control Group (CG, A), Ozone Gas Group (OGG, C), and Ozonized Oil Group (OOG, E) exhibited similar characteristics, with features of chronic inflammation ranging from moderate to intense. By day 10, the CG (B), OGG (D), and OOG (F) showed histological aspects consistent with later stages of tissue repair and mild inflammation. Light microscopy, hematoxylin and eosin staining, 100× (ICS–UFBA)

	5º dia	10º dia
CG	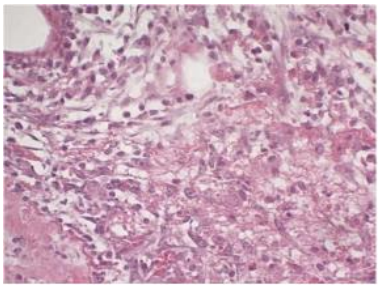 A	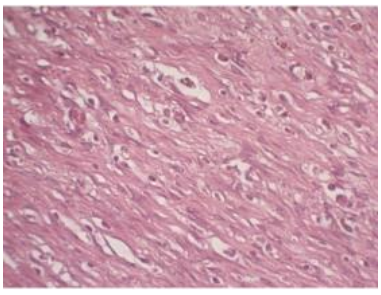 B

ISSN: 2675-6218 - RECIMA21
This article is published in Open Access under the Creative Commons Attribution 4.0 International (CC-BY) license, which allows unrestricted use, distribution and reproduction in any medium, provided the original author and source are credited.

REVISTA CIENTÍFICA - RECIMA21 ISSN 2675-6218

OGG	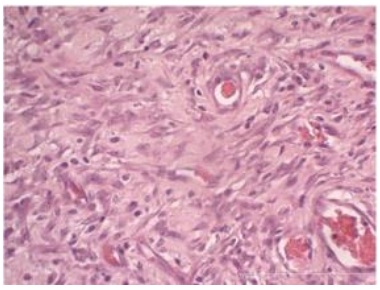 C	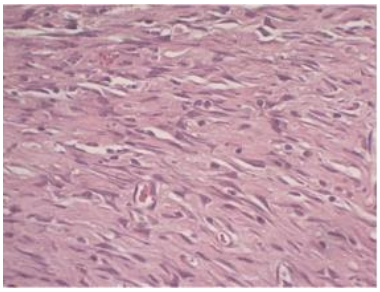 D
OOG	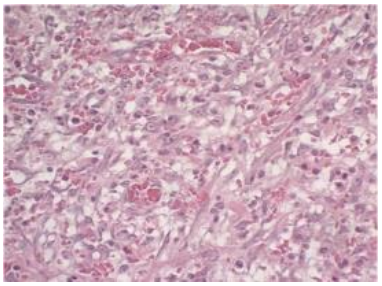 E	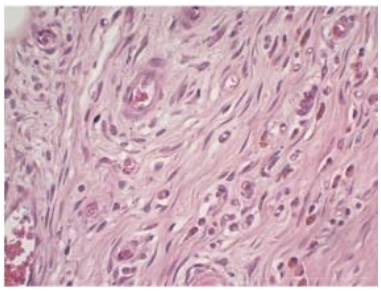 F

Figure 3. Histomorphometric analysis of the experimental groups. Photomicrographs of histological skin sections from Wistar rats showing the standardized cutaneous wound at 5 and 10 postoperative days. Numerous mast cells are observed in the dermis of all groups, particularly in the treated ones. On day 5, the Control Group (CG, A), Ozone Gas Group (OGG, C), and Ozonized Oil Group (OOG, E) exhibited a higher number of intact mast cells. By day 10, the CG (B), OGG (D), and OOG (F) exhibited histological features characteristic of later phases of tissue repair. Light microscopy, toluidine blue staining, 400× (ICS–UFBA)

	Day 5	Day 10
CG	A 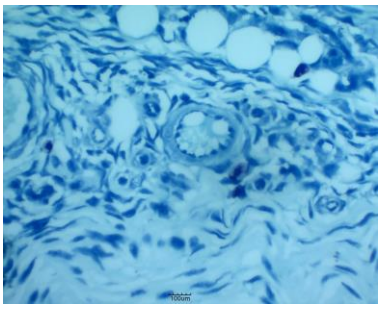	B 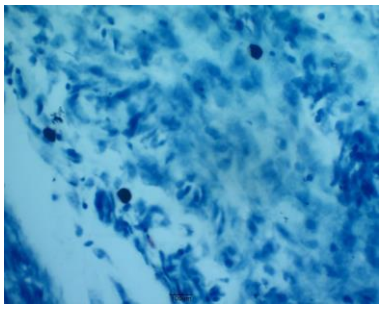
	C	D

ISSN: 2675-6218 - RECIMA21
This article is published in Open Access under the Creative Commons Attribution 4.0 International (CC-BY) license, which allows unrestricted use, distribution and reproduction in any medium, provided the original author and source are credited.

REVISTA CIENTÍFICA - RECIMA21 ISSN 2675-6218

OGG	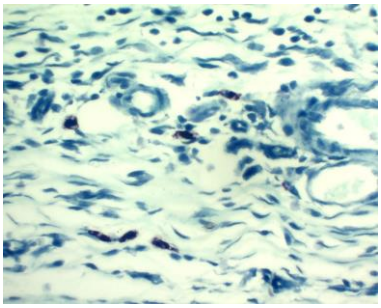	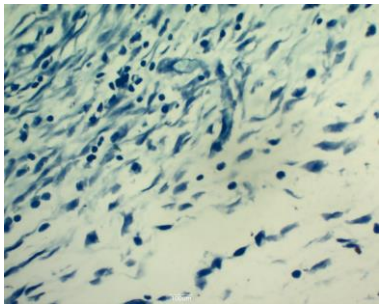
OOG	E 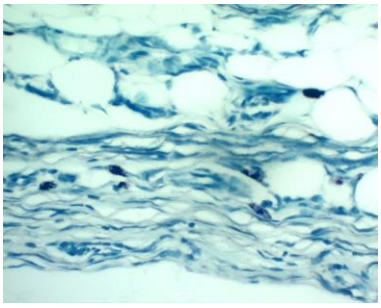	F 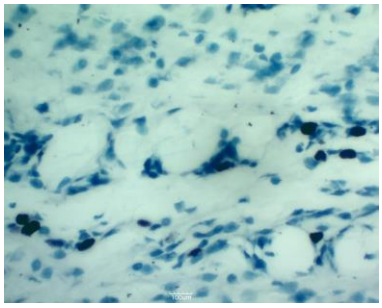

3. DISCUSSION

This experimental study investigated the effects of ozone gas and ozonized oil on tissue repair parameters, specifically the mononuclear inflammatory infiltrate and the number of intact and degranulated mast cells in rat cutaneous wounds, at 5 and 10 days after wound induction. Semi-quantitative and histomorphometric analyses enabled the characterization of the cellular dynamics during the proliferative phase of healing, a critical stage for granulation tissue formation and extracellular matrix synthesis.

Previous studies have shown that ozone therapy can induce controlled oxidative stress, which may attenuate inflammation and accelerate its resolution during wound repair (De Sire *et al*., 2022; Smith *et al*., 2017). In the present study, the analysis focused on the proliferative phase, characterized by a predominance of mononuclear inflammatory cells in the granulation tissue. The Control and Ozonized Oil groups demonstrated a tendency for the mononuclear inflammatory infiltrate to progress from intense to very intense between days 5 and 10, with statistical significance observed only in the Control group. In contrast, this variable remained unchanged in the Ozone Gas group, suggesting a potential anti-inflammatory effect of ozone gas during the proliferative phase of repair.

These findings are consistent with the results reported by Bacci *et al*., (2021) and Rodrigues *et al.,* (2019), who also observed a decrease in both polymorphonuclear and mononuclear inflammatory cells following ozone therapy. In experimental models using rats, the authors described

This article is published in Open Access under the Creative Commons Attribution 4.0 International (CC-BY) license, which allows unrestricted use, distribution and reproduction in any medium, provided the original author and source are credited.

a marked reduction in neutrophils and monocytes/macrophages within the wound bed, corresponding to a transition from the acute inflammatory phase to the regenerative phase, when extracellular matrix production, angiogenesis, and re-epithelialization become predominant.

The literature further highlights ozone's dual modulatory potential as both a pro- and anti-inflammatory agent. Its initial effects may involve the controlled activation of inflammatory pathways, mediated by factors such as NF-κB, which stimulate the release of pro-inflammatory cytokines. Subsequently, ozone appears to promote antioxidant defense mechanisms that limit oxidative stress (LIU *et al.* 2018). Moreover, ozone has been shown to induce mast cell–mediated release of nitric oxide and vasoactive substances, enhance local blood perfusion, and accelerate tissue repair. The activation of antioxidant enzymes such as catalase and glutathione peroxidase by mast cells may further contribute to cytoprotection and the resolution of inflammation (Saglam *et al.,* 2019. Pires *et al.,* (2021) also reported that ozone therapy enhances the resolution of inflammation and improves the efficiency of tissue repair, particularly during the later stages of healing (Atiakshin *et al.,* 2020). The present findings support this notion, suggesting that the mode of ozone administration, specifically, subcutaneous insufflation at the wound margins, may influence the anti-inflammatory response. It is therefore plausible that different routes of ozone application modulate inflammatory processes in distinct ways, depending on dosage, delivery method, and local tissue environment (Xavier *et al.,* 2021).

A primary outcome of the present study was the marked influence of ozone therapy on mast cell (MC) dynamics. Recent research has demonstrated that MCs display distinct biological profiles throughout the wound-healing process, undergoing degranulation during both the inflammatory and proliferative phases. These cells, present in nearly all vascularized tissues, perform diverse functions, including the release of vasoactive amines and the synthesis of cytokines, chemokines, and growth factors (Shiota *et al.,* 2021). Moreover, MCs play pivotal regulatory roles in immune defense, as they are among the first cells recruited to the site of injury via chemotactic signals. They actively participate in inflammatory and hypersensitivity reactions, as well as in antimicrobial defense (Bacci *et al.*, 2022; Smith *et al.,* 2017).

Diapedesis is promoted by vasodilation and increased vascular permeability - processes primarily mediated by histamine and serotonin released during MC degranulation (DONG *et al.* 2025). Additionally, MCs modulate the tissue microenvironment by secreting glycosaminoglycans, which initiate fibrinogen activation. The subsequent deposition of fibrin in the extracellular matrix (ECM), organized into a fibrous network, stimulates the biosynthesis of fibrillar components such as collagen and elastin (Atiakshin *et al.,* 2023).

In this context, the increased number of mast cells, particularly degranulated ones, observed in the ozone-treated groups between days 5 and 10, suggests that ozone therapy may biomodulate MC behavior during the proliferative phase of healing. This finding reinforces the hypothesis that

This article is published in Open Access under the Creative Commons Attribution 4.0 International (CC-BY) license, which allows unrestricted use, distribution and reproduction in any medium, provided the original author and source are credited.

MCs actively participate not only in the inflammatory phase but also in the proliferative and remodeling stages of tissue repair. However, it remains to be determined whether this enhanced degranulation directly influences other repair variables, particularly those related to ECM remodeling (Huang *et al.,* 2010).

Shiota *et al.,* (2009) highlighted the crucial involvement of MCs in the remodeling phase, particularly through the release of mediators that stimulate collagen biosynthesis and neoangiogenesis. Although collagen fiber formation was not directly assessed in the present study, the higher prevalence of degranulated MCs in the treated groups may indicate a role in advancing the repair process, potentially through the release of regulatory cytokines and growth factors that promote ECM synthesis (Atiakshin *et al.,* 2020).

Two distinct ozone application modalities, gas and oil, were employed in this study. Topical ozone-based treatments, including ozonized oils and ozonized water, have gained increasing attention and are being widely adopted worldwide as adjunctive wound-healing therapies (Da Silva *et al.,* 2022). Various production methods are used to prepare these compounds, with ozonized oils demonstrating greater chemical stability. Due to their antimicrobial properties, these oils are empirically applied in the management of superficial bacterial and fungal infections (Silva *et al.,* 2021). However, the lack of standardization in peroxide concentration in ozonized oils represents a significant limitation, hindering the determination of an optimal range to achieve therapeutic effects across different phases of wound healing.

Although this study's findings indicate that ozone application modulates the inflammatory response and MC activity, several limitations must be acknowledged. Molecular analyses to elucidate the underlying mechanisms were not performed, nor were parameters such as collagen fiber organization or vascular density evaluated, variables that could offer deeper insights into ozone's reparative effects (Vinnik *et al*., 2022). Future studies integrating histological, biochemical, and molecular approaches are warranted to better characterize ECM components such as collagen and elastin, thereby elucidating the precise mechanisms through which ozone enhances tissue repair (Dunnill *et al.,* 2017). Another limitation of the present study concerns the absence of immunohistochemical analysis with monoclonal antibodies for endothelial cells, such as CD31 and VEGF, which is also encouraged by the authors, since it could increase the degree of sensitivity and specificity in evaluating the participation of endothelial cells in repair and their correlation with the other variables of this study.

Despite these limitations, the present findings support the hypothesis that ozone therapy, particularly in its oil-based form, can modulate inflammation and MC function during tissue repair (Piipponen *et al*., 2020). The greater number of degranulated mast cells in the treated groups suggests their involvement in the release of mediators that promote matrix biosynthesis and neoangiogenesis, both essential processes for efficient wound healing (Zhang *et al.,* 2022).

This article is published in Open Access under the Creative Commons Attribution 4.0 International (CC-BY) license, which allows unrestricted use, distribution and reproduction in any medium, provided the original author and source are credited.

Finally, although experimental evidence supports the therapeutic potential of ozone, its clinical application is limited by a lack of systematic review evidence. Its clinical application is limited. Systematic reviews, such as that by Liu *et al.,* (2015), highlight the low quality of the studies available to date and emphasize the need for research with greater methodological rigor to establish standardized, reliable treatment protocols and safety profiles.

4. CONCLUSION

Although no significant modulation of the mononuclear inflammatory infiltrate was observed, ozone therapy effectively influenced mast cell dynamics during tissue repair, particularly on the fifth day of healing, regardless of the route of administration. The increase in degranulated mast cells in the ozone-treated groups suggests a biomodulatory role for ozone in enhancing cellular activity associated with extracellular matrix synthesis and angiogenesis. These findings support the potential of ozone therapy — especially in its topical oil-based form — as an adjuvant strategy to optimize wound healing. Further molecular and clinical investigations are warranted to clarify the underlying mechanisms and to suggest standardized therapeutic protocols.

REFERENCES

ALVARENGA, M. O. P. *et al.* Safety and effectiveness of copaiba oleoresin (C. reticulata Ducke) on inflammation and tissue repair of oral wounds in rats. **International Journal of Molecular Sciences**, v. 21, n. 10, p. 3568, 2020. DOI: https://doi.org/10.3390/ijms21103568.

ATIAKSHIN, D. *et al.* Mast cells in regeneration of the skin in burn wound with special emphasis on molecular hydrogen effect. **Pharmaceuticals**, v. 16, n. 3, p. 348, 2023. DOI: https://doi.org/10.3390/ph16030348

ATIAKSHIN, D.; BUCHWALOW, I.; TIEMANN, M. Mast cells and collagen fibrillogenesis. **Histochemistry and Cell Biology**, v. 154, p. 21–40, 2020. DOI: https://doi.org/10.1007/s00418-020-01875-9..

BACCI, S. Fine regulation during wound healing by mast cells: a physiological role not yet clarified. **International Journal of Molecular Sciences**, v. 23, n. 3, p. 1820, 2022. DOI: https://doi.org/10.3390/ijms23031820.

DA SILVA, A. C. *et al.* Ozonioterapia no tratamento de feridas em cães diabéticos. **Brazilian Journal of Development**, v. 8, n. 8, p. 56860–56871, 2022. DOI: https://doi.org/10.34117/bjdv8n8-133.

DAMY, S. B. *et al.* Aspectos fundamentais da experimentação animal – aplicações em cirurgia experimental. **Revista da Associação Médica Brasileira**, v. 56, n. 1, p. 103–111, 2010. DOI: https://doi.org/10.1590/S0104-42302010000100024.

DE SIRE, A. et al. Oxygen-ozone therapy for reducing pro-inflammatory cytokines serum levels in musculoskeletal and temporomandibular disorders: a comprehensive review. **International Journal of Molecular Sciences**, v. 23, n. 5, p. 2528, 2022. DOI: https://doi.org/10.3390/ijms23052528.

This article is published in Open Access under the Creative Commons Attribution 4.0 International (CC-BY) license, which allows unrestricted use, distribution and reproduction in any medium, provided the original author and source are credited.

DONG, J. *et al.* Mast cells in diabetes and diabetic wound healing. **Advances in Therapy**, v. 37, p. 4519–4537, 2020. DOI: https://doi.org/10.1007/s12325-020-01499-4.

DUNNILL, C. *et al.* Reactive oxygen species (ROS) and wound healing: the functional role of ROS and emerging ROS-modulating technologies for augmentation of the healing process. **International Wound Journal,** v. 14, n. 1, p. 89–96, 2017.

EBRAHIMI, P. *et al.* Effect of photobiomodulation in secondary intention gingival wound healing: a systematic review and meta-analysis. **BMC Oral Health**, v. 21, p. 258, 2021. DOI: https://doi.org/10.1186/s12903-021-01611-2.

EVALUATION of antibacterial activity of sunflower oil: support for nursing. **Research, Society and Development,** v. 10, n. 9, p. e8710917941, 2021. DOI: https://doi.org/10.33448/rsd-v10i9.17941. Disponível em: https://rsdjournal.org/rsd/article/view/17941.

GONZALEZ, A. C. O. *et al.* Wound healing: a literature review. **Anais Brasileiros de Dermatologia**, v. 91, n. 5, p. 614–620, 2016. DOI: https://doi.org/10.1590/abd1806-4841.20164741.

HUANG, H. J. *et al.* Effect of ozone water on the inflammation and repair in infected wounds. **Nan Fang Yi Ke Da Xue Xue Bao**, v. 30, n. 3, p. 515–518, 2010.

LIU, J. *et al.* Ozone therapy for treating foot ulcers in people with diabetes. **Cochrane Database of Systematic Reviews**, n. 10, 2015. Art. n. CD008474. DOI: https://doi.org/10.1002/14651858.CD008474.pub2.

LIU, L. *et al.* Ozone therapy for skin diseases: cellular and molecular mechanisms. **International Wound Journal**, v. 20, n. 6, p. 2376–2385, 2022.

MEDRADO, A. R. *et al.* Influence of low level laser therapy on wound healing and its biological action upon myofibroblasts. **Lasers in Surgery and Medicine**, v. 32, n. 3, p. 239–244, 2003. DOI: https://doi.org/10.1002/lsm.10126

PIIPPONEN, M.; LI, D.; LANDÉN, N. X. The immune functions of keratinocytes in skin wound healing. **International Journal of Molecular Sciences**, v. 21, n. 22, p. 8790, 2020. DOI: https://doi.org/10.3390/ijms21228790..

PIRES, J. R. *et al.* Effect of systemic ozone therapy as a biomodulator of tissue regeneration and inflammatory response in rats. **Revista de Odontologia da UNESP**, v. 50, p. e20210046, 2021. DOI: https://doi.org/10.1590/1807-2577.04621..

RODRIGUES, M. *et al.* Wound healing: a cellular perspective. **Physiological Reviews**, v. 99, n. 1, p. 665–706, 2019. DOI: https://doi.org/10.1152/physrev.00067.2017..

SAGLAM, E. *et al.* Evaluation of the effect of topical and systemic ozone application in periodontitis: an experimental study in rats. **Journal of Applied Oral Science**, v. 28, p. e20190140, 2019. DOI: https://doi.org/10.1590/1678-7757-2019-0140..

SHIOTA, N. *et al.* Pathophysiological role of skin mast cells in wound healing after scald injury: study with mast cell-deficient W/Wv mice. International Archives of Allergy and Immunology, v. 151, p. 80–88, 2009.

This article is published in Open Access under the Creative Commons Attribution 4.0 International (CC-BY) license, which allows unrestricted use, distribution and reproduction in any medium, provided the original author and source are credited.

REVISTA CIENTÍFICA - RECIMA21 ISSN 2675-6218

SMITH, N. L. *et al.* Ozone therapy: an overview of pharmacodynamics, current research, and clinical utility. **Medical Gas Research**, v. 7, n. 3, p. 212–219, 2017.

VIEBAHN-HAENSLER, R.; LEÓN FERNÁNDEZ, O. S. Mitochondrial dysfunction, its oxidative stress-induced pathologies and redox bioregulation through low-dose medical ozone: a systematic review. **Molecules**, v. 29, n. 12, p. 2738, 2024. DOI: https://doi.org/10.3390/molecules29122738.

VINNIK, Y. S. *et al*. Effectiveness of ozone therapy and ultrasound in regeneration of an infected wound in an experiment. **Siberian Medical Review**, 2022.

XAVIER, P. B. Application of ozonetherapy in the treatment of skin injuries in the elderly. **Research, Society and Development**, v. 10, n. 17, p. e229101724682, 2021. DOI: https://doi.org/10.33448/rsd-v10i17.24682. Disponível em: https://rsdjournal.org/rsd/article/view/24682.

ZHANG, X. *et al.* Elastic fibre proteins in elastogenesis and wound healing. **International Journal of Molecular Sciences**, v. 23, p. 4087, 2022. DOI: https://doi.org/10.3390/ijms23084087.

This article is published in Open Access under the Creative Commons Attribution 4.0 International (CC-BY) license, which allows unrestricted use, distribution and reproduction in any medium, provided the original author and source are credited.