v7.n12.2026

SCIENTIFIC JOURNAL - RECIMA21 ISSN 2675-6218

MANDIBULAR SULCOPLASTY USING THE MODIFIED KAZANJIAN TECHNIQUE FOR PROSTHETIC REHABILITATION: A CASE REPORT

SULCOPLASTIA MANDIBULAR PELA TÉCNICA DE KAZANJIAN MODIFICADA PARA REABILITAÇÃO PROTÉTICA: RELATO DE CASO

SULCOPLASTIA MANDIBULAR MEDIANTE LA TÉCNICA DE KAZANJIAN MODIFICADA PARA LA REHABILITACIÓN PROTÉSICA: REPORTE DE CASO

Vinícius Franzão Ganzaroli[1], Kayky Ferreira de Souza[2], Maria Eloiza de Souza Thomaz[3], Caio Jesus de Souza[2], Rafael Vinhal Silva[4], Juliana de Aguiar Silveira Meira[5], Ana Carolina Zucon Bacelar Marcolino[6], Osvaldo Magro Filho[7]

https://doi.org/10.47820/recima21.v7i12.9768

PUBLISHED: 12/2026

ABSTRACT

Progressive alveolar ridge resorption following tooth loss may lead to reduced vestibular depth and altered muscle attachments, compromising the retention and stability of mandibular complete dentures. In such cases, sulcoplasty may be indicated to deepen the vestibule and improve anatomical conditions for prosthetic rehabilitation. This study reports the case of an 83-year-old edentulous male patient who experienced difficulty using his mandibular complete denture due to instability during function. Clinical examination revealed mandibular alveolar ridge resorption associated with high muscle attachments and reduced vestibular depth. Sulcoplasty was performed using the modified Kazanjian technique, involving the preparation of a partial-thickness flap, periosteal dissection and repositioning, followed by suturing the periosteum to the labial mucosa and the alveolar mucosa to the periosteal base, thereby deepening and stabilizing the vestibular fornix. Postoperative follow-up was conducted weekly. At 30 days, adequate healing was observed, with no signs of infection and maintenance of the surgically achieved vestibular depth. During the fabrication of a new mandibular complete denture, the patient reported improved denture retention and stability. It can be concluded that the modified Kazanjian technique yielded a satisfactory clinical outcome, providing favorable anatomical conditions for mandibular prosthetic rehabilitation. However, the absence of objective measurements and the limited 30-day follow-up period restrict the assessment of the long-term stability of the results.

KEYWORDS: *Vestibuloplasty. Mandible. Oral Surgery.*

RESUMO

A reabsorção progressiva do rebordo alveolar após a perda dentária pode resultar em redução da profundidade vestibular e alteração das inserções musculares, comprometendo a retenção e a estabilidade das próteses totais mandibulares. Nesses casos, a sulcoplastia pode ser indicada para o aprofundamento do vestíbulo e adequação das condições anatômicas à reabilitação protética.

[1] Master's degree holder and PhD candidate in Oral and Maxillofacial Surgery and Traumatology at the Araçatuba School of Dentistry, São Paulo State University (FOA-UNESP).
[2] Undergraduate students in Dentistry at the Araçatuba School of Dentistry, São Paulo State University (FOA-UNESP).
[3] Undergraduate student in Dentistry at the Araçatuba School of Dentistry, São Paulo State University (FOA-UNESP).
[4] Undergraduate student in Dentistry at Universidade Brasil (UB), Fernandópolis Campus, São Paulo, Brazil.
[5] Master's degree holder and PhD candidate in Oral and Maxillofacial Surgery and Traumatology at the Araçatuba School of Dentistry, São Paulo State University (FOA-UNESP).
[6] PhD in Oral and Maxillofacial Surgery and Traumatology from the Araçatuba School of Dentistry, São Paulo State University (FOA-UNESP).
[7] Professor with a PhD in Oral and Maxillofacial Surgery and Traumatology at the Araçatuba School of Dentistry, São Paulo State University (FOA-UNESP).

This article is published in open access under the Creative Commons Attribution 4.0 International (CC BY 4.0) license, which permits unrestricted use, distribution, and reproduction in any medium, provided that the original author and source are credited.

Este trabalho relata o caso de um paciente do sexo masculino, 83 anos, desdentado total, que apresentou dificuldade na utilização da prótese total mandibular devido à sua instabilidade durante a função. Ao exame clínico, observou-se reabsorção do rebordo alveolar mandibular, associada a inserções musculares altas e redução da profundidade vestibular. Foi realizada sulcoplastia pela técnica de Kazanjian modificada, com confecção de retalho de espessura parcial, descolamento e reposicionamento do periósteo, seguido da sutura do periósteo à mucosa labial e da mucosa alveolar à base do periósteo, promovendo o aprofundamento e a estabilização do fundo de vestíbulo. O acompanhamento pós-operatório foi realizado semanalmente. Aos 30 dias, observou-se adequada cicatrização, ausência de sinais de infecção e manutenção da profundidade vestibular obtida cirurgicamente. Durante a confecção da nova prótese total mandibular, o paciente relatou melhora da retenção e estabilidade protética. Conclui-se que a técnica de Kazanjian modificada apresentou resultado clínico satisfatório, favorecendo condições anatômicas adequadas para a reabilitação protética mandibular. Entretanto, a ausência de mensurações objetivas e o acompanhamento limitado a 30 dias restringem a avaliação da estabilidade dos resultados em longo prazo.

PALAVRAS-CHAVE: Vestibuloplastia. Mandíbula. Cirurgia Bucal.

RESUMEN

La reabsorción progresiva del reborde alveolar tras la pérdida dentaria puede provocar una reducción de la profundidad vestibular y alteraciones en las inserciones musculares, comprometiendo la retención y la estabilidad de las prótesis completas mandibulares. En estos casos, la sulcoplastia puede estar indicada para profundizar el vestíbulo y mejorar las condiciones anatómicas para la rehabilitación protésica. Este trabajo presenta el caso de un paciente masculino de 83 años, edéntulo total, que presentaba dificultades para utilizar la prótesis completa mandibular debido a su inestabilidad durante la función. En el examen clínico, se observó reabsorción del reborde alveolar mandibular, asociada a inserciones musculares altas y reducción de la profundidad vestibular. Se realizó una sulcoplastia mediante la técnica de Kazanjian modificada, con la confección de un colgajo de espesor parcial, disección y reposicionamiento del periostio, seguidos de la sutura del periostio a la mucosa labial y de la mucosa alveolar a la base del periostio, favoreciendo la profundización y estabilización del fondo del vestíbulo. El seguimiento posoperatorio se realizó semanalmente. A los 30 días, se observó una cicatrización adecuada, ausencia de signos de infección y mantenimiento de la profundidad vestibular obtenida quirúrgicamente. Durante la confección de la nueva prótesis completa mandibular, el paciente refirió una mejora en la retención y estabilidad protésicas. Se concluye que la técnica de Kazanjian modificada presentó un resultado clínico satisfactorio, favoreciendo condiciones anatómicas adecuadas para la rehabilitación protésica mandibular. Sin embargo, la ausencia de mediciones objetivas y el seguimiento limitado a 30 días restringen la evaluación de la estabilidad de los resultados a largo plazo.

PALABRAS CLAVE*: Vestibuloplastia. Mandíbula. Cirugía Bucal.*

1. INTRODUCTION

Tooth loss constitutes a major oral health problem and is associated with consequences that may compromise oral function and individuals' quality of life (Leite *et al.*, 2026). In addition, recent evidence indicates that edentulism is associated with a higher risk of impaired nutritional status

This article is published in open access under the Creative Commons Attribution 4.0 International (CC BY 4.0) license, which permits unrestricted use, distribution, and reproduction in any medium, provided that the original author and source are credited.

in older adults, while, among edentulous individuals, denture use has been associated with a more favorable nutritional status (Dąbrowski *et al.*, 2026).

Edentulous patients experience progressive resorption of the residual alveolar ridge, which may result in significant changes in mandibular anatomy. Severe ridge resorption may be associated with reduced vestibular depth and alterations in the relationship between muscle attachments and the alveolar ridge (Patil *et al.*, 2025). These changes may limit the extension of the denture base and promote denture displacement during functional movements, making it difficult to achieve adequate retention, stability, and patient comfort (Kumar *et al.*, 2016; Patil *et al.*, 2025).

In this context, vestibuloplasty constitutes a surgical alternative aimed at deepening the vestibule through the repositioning of soft tissues and muscle attachments, thereby providing more favorable anatomical conditions for extending the denture base and improving prosthetic stability (Ponzoni *et al.*, 2013; Kumar *et al.*, 2016). Several vestibuloplasty techniques have been described for the treatment of mandibular ridges associated with reduced vestibular depth, including approaches involving secondary epithelialization and techniques associated with the use of mucosal or skin grafts. Among the techniques involving secondary epithelialization, the Kazanjian technique, subsequently modified by different authors, is noteworthy. This technique aims to deepen the vestibule and reposition the soft tissues and may be used as a pre-prosthetic procedure in patients with unfavorable anatomical conditions (Kazanjian, 1935; Ponzoni *et al.*, 2013; Kumar *et al.*, 2016).

The modified Kazanjian technique is based on the repositioning of soft tissues and muscle attachments, leaving a denuded area that heals by secondary intention, with the aim of establishing and maintaining a deeper vestibular sulcus. Modifications of the original technique have been proposed over time to minimize limitations related to relapse and scar contraction, thereby favoring maintenance of the achieved vestibular depth and, consequently, more favorable anatomical conditions for prosthetic rehabilitation (Ponzoni *et al.*, 2013; Kumar *et al.*, 2016; Patil *et al.*, 2025). The modified technique has also been investigated in dentate areas, with outcomes related to the maintenance of vestibular depth and periodontal tissue conditions (Wyrębek *et al.*, 2021).

Despite the availability of different techniques for vestibular deepening, factors related to the healing process and the characteristics of the tissues involved may affect the maintenance of the achieved depth. Therefore, the choice of technique should take into consideration the patient's anatomical conditions, the extent of alveolar ridge resorption, and the objective of the intervention, particularly when the goal is to improve conditions for rehabilitation with a removable prosthesis.

This article is published in open access under the Creative Commons Attribution 4.0 International (CC BY 4.0) license, which permits unrestricted use, distribution, and reproduction in any medium, provided that the original author and source are credited.

In this context, the modified Kazanjian technique remains an alternative of interest for edentulous patients with reduced vestibular depth and compromised prosthetic stability.

Therefore, the present study aims to report a clinical case of mandibular sulcoplasty performed using the modified Kazanjian technique in an edentulous patient with alveolar ridge resorption and reduced vestibular depth, with the purpose of providing favorable anatomical conditions for rehabilitation with a mandibular complete denture.

2. CASE REPORT

An 83-year-old male patient, White, was referred by a dental surgeon to the Department of Oral and Maxillofacial Surgery and Traumatology at the Araçatuba School of Dentistry (FOA-UNESP) for evaluation of the mandibular region. According to the referral, the patient presented with insufficient mandibular alveolar ridge height for the proper fabrication and placement of a complete denture.

During the medical history interview, the patient reported a diagnosis of type 2 diabetes mellitus and systemic arterial hypertension, both controlled, and continuous use of metformin 500 mg and losartan 50 mg once daily. He denied any drug allergies or deleterious habits. A panoramic radiograph was obtained to assess the mandibular bone structure and evaluate the residual alveolar ridge, which presented marked atrophy (Figure 1).

Figure 1. Panoramic radiograph showing mandibular residual alveolar ridge atrophy

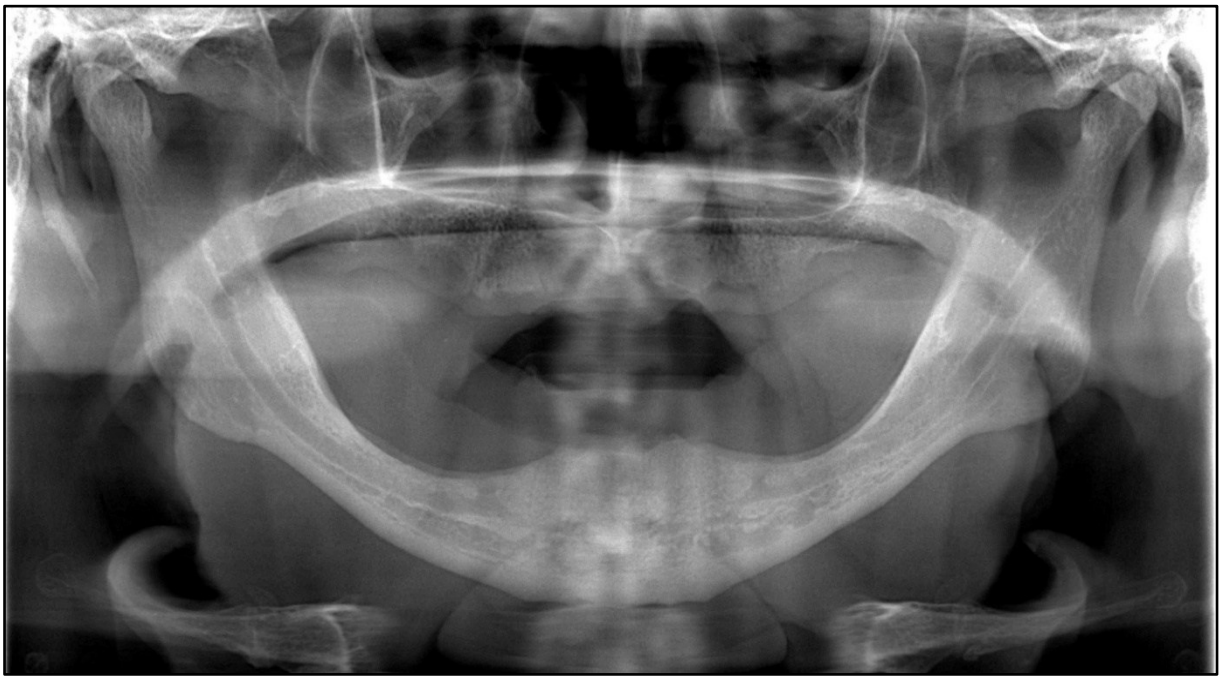

Source: Author's own work.

This article is published in open access under the Creative Commons Attribution 4.0 International (CC BY 4.0) license, which permits unrestricted use, distribution, and reproduction in any medium, provided that the original author and source are credited.

Intraoral clinical examination revealed complete edentulism, with the patient wearing only a maxillary complete denture. He reported being unable to use the mandibular complete denture because of its instability during function. Examination of the mandibular alveolar ridge revealed physiological resorption of the alveolar process associated with high muscle attachments, compromising the stability and retention of the mandibular denture (Figure 2A). Based on the clinical findings, mandibular sulcoplasty using the modified Kazanjian technique was indicated, with the aim of increasing vestibular depth, improving the anatomical conditions for denture retention and stability, and consequently facilitating the patient's prosthetic rehabilitation.

Following detailed surgical planning, intraoral antisepsis was performed using 0.12% chlorhexidine digluconate, followed by extraoral antisepsis with a 10% povidone-iodine (PVP-I) solution. Subsequently, bilateral terminal infiltration anesthesia was administered in the region of the mental nerves, complemented by local anesthetic infiltration into the vestibular fornix of the anterior mandibular region, using 2% lidocaine hydrochloride with epinephrine at a concentration of 1:100,000.

Subsequently, using a No. 15 scalpel blade, the limits of the area to be deepened were delineated. Laterally, the posterior border of the depressor labii inferioris muscle was used as a reference, while anteriorly, the incision extended approximately 1.5 times the desired depth of the new vestibular sulcus. A partial-thickness flap was then raised, with careful dissection of the mucosa toward the alveolar crest, creating a mucosal pedicle (Figure 2B). The periosteum was then incised at the alveolar crest and carefully elevated from the underlying bone, preserving its integrity, with the dissection extended toward the mandibular base (Figures 2C and 3).

The periosteum was subsequently repositioned and sutured to the previously incised labial mucosa using a continuous spiral suture with 4-0 polyglactin suture (Figure 2D). The alveolar mucosa was then sutured to the periosteum at the previously established depth for the new vestibular sulcus, using simple interrupted sutures with 4-0 polyglactin, thereby establishing the depth of the new vestibular fornix (Figures 2E and 2F). As an absorbable suture material was used, suture removal was not required.

This article is published in open access under the Creative Commons Attribution 4.0 International (CC BY 4.0) license, which permits unrestricted use, distribution, and reproduction in any medium, provided that the original author and source are credited.

Figure 2. Surgical procedure for sulcoplasty. A: Initial appearance of the mandibular alveolar ridge; B: Incision of the vestibular mucosa and creation of a partial-thickness flap; C: Periosteal elevation toward the mandibular base; D: Repositioning and suturing of the periosteum to the labial mucosa; E: Suturing of the alveolar mucosa to the periosteum at its base; F: Final appearance of the sulcoplasty, showing the increased depth of the vestibular fornix.

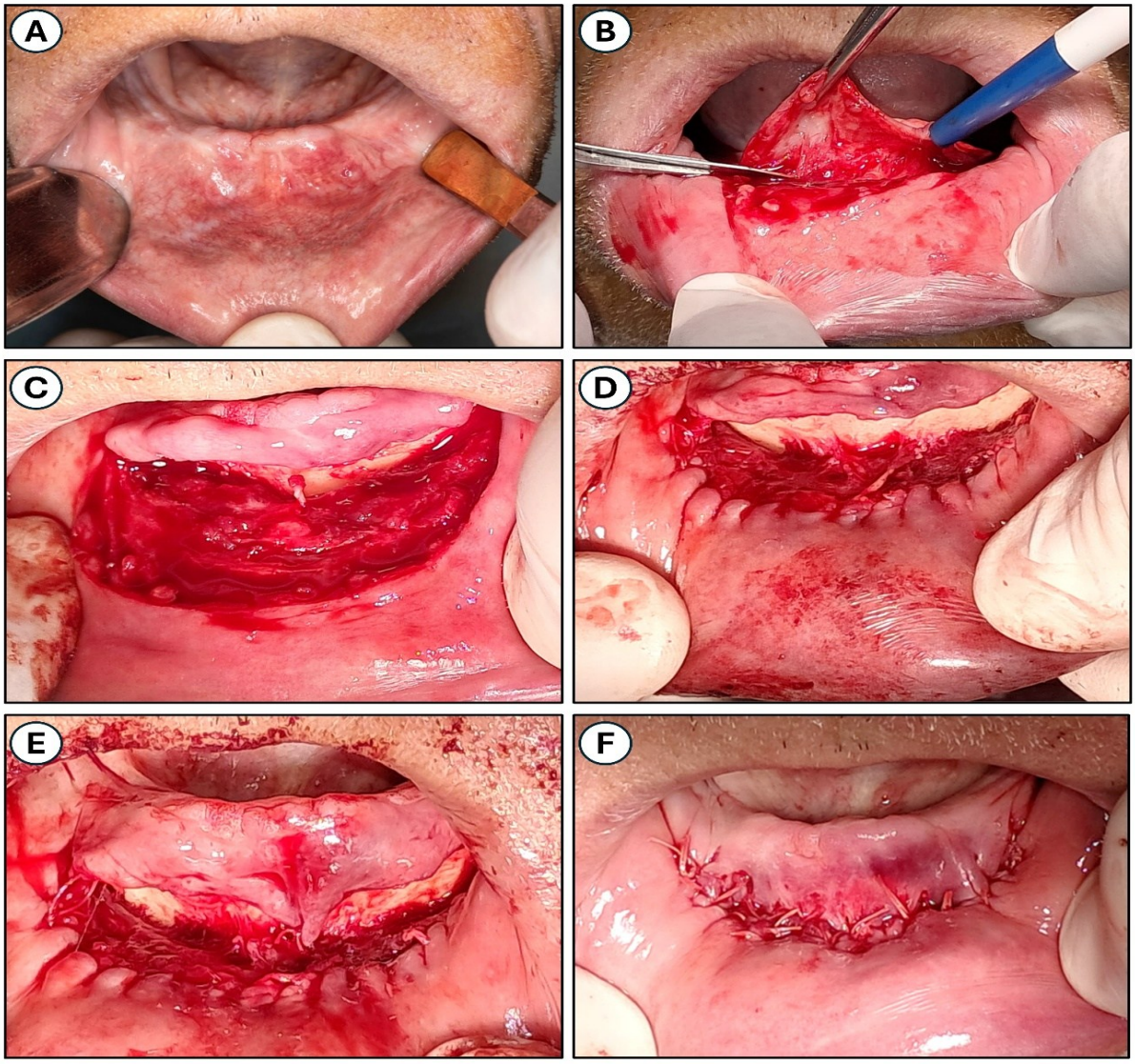

Source: Author's own work.

This article is published in open access under the Creative Commons Attribution 4.0 International (CC BY 4.0) license, which permits unrestricted use, distribution, and reproduction in any medium, provided that the original author and source are credited.

Figure 3. Schematic representation of the incision design for sulcoplasty. The diagram illustrates the incisions performed to release the soft tissues and allow repositioning and deepening of the vestibular mucosa, with the incision lines extending from the alveolar region toward the vestibular area

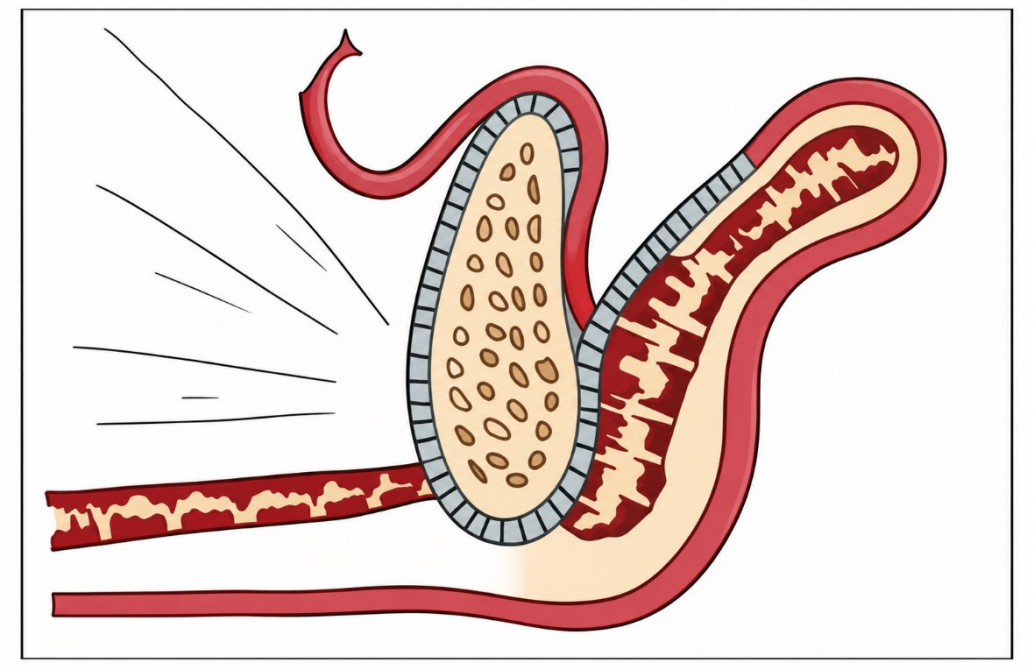

Source: Image adapted from Magro-Filho and de Carvalho (1994), with AI-assisted modifications.

For the postoperative period, the patient was prescribed amoxicillin (500 mg every 8 hours for 7 days), nimesulide (100 mg every 12 hours), and dipyrone (500 mg every 6 hours). Mouth rinses with 0.12% chlorhexidine digluconate were also recommended twice daily for 14 days.

The patient was followed up through weekly appointments. At 30 days postoperatively, no signs of infection were observed, and the tissues exhibited satisfactory healing, with maintenance of the surgically achieved vestibular depth (Figure 4). In view of the favorable clinical outcome, the patient was discharged from surgical follow-up and referred to the Complete Denture Prosthodontics Department for the fabrication of a new mandibular complete denture.

Written informed consent was obtained from the patient for the publication of this case report and the accompanying clinical photographs.

This article is published in open access under the Creative Commons Attribution 4.0 International (CC BY 4.0) license, which permits unrestricted use, distribution, and reproduction in any medium, provided that the original author and source are credited.

Figure 4. Final appearance of the mandibular alveolar ridge after 30 days of postoperative follow-up



Source: Author's own work.

3. DISCUSSION

Among the prerequisites for successful prosthetic rehabilitation, whether with conventional or implant-supported partial or complete dentures, a well-preserved alveolar ridge with adequate vestibular depth and attached gingiva is particularly important (Ponzoni *et al.*, 2013). An ideal alveolar ridge should exhibit adequate and uniform bone height and be free of any pathology (House, 1930). However, considering that tooth loss is followed by substantial alveolar bone loss that continues progressively over the years, preservation of an alveolar ridge with ideal characteristics is relatively uncommon (Marzola, 2002).

In this context, although bone regeneration techniques allow the reconstruction of atrophic ridges of varying dimensions, their indications and predictability may be influenced by local and systemic factors. Furthermore, grafting procedures are associated with potential intraoperative and postoperative complications, such as graft exposure, infection, soft tissue dehiscence, resorption, and graft failure, in addition to increased morbidity and procedure-related costs (Sanz-Sánchez *et al.*, 2022). When the primary goal of rehabilitation is to restore vestibular depth and improve the supporting conditions for a prosthesis, procedures targeting soft tissues may be considered, often eliminating the need for bone reconstruction. Gingival grafting procedures can

This article is published in open access under the Creative Commons Attribution 4.0 International (CC BY 4.0) license, which permits unrestricted use, distribution, and reproduction in any medium, provided that the original author and source are credited.

also increase vestibular depth; however, they have important disadvantages, including the need for a second surgical site for graft harvesting and greater postoperative pain compared with sulcoplasty (Mohanty *et al.*, 2025).

In this context, sulcoplasty represents a promising option for increasing vestibular depth. It is a mucogingival surgical procedure aimed at improving the anatomical relationship between the gingiva and the oral mucosa. Although it has certain limitations, it offers favorable clinical outcomes, a relatively rapid recovery, lower costs, and no need for hospitalization or additional grafting procedures.

Several techniques for vestibular deepening have been described, including the original techniques developed by Kazanjian (1935) and subsequent modifications proposed by Godwin (1947), Trauner (1952), Clark (1953), and Tortorelli (1968). The classical Kazanjian technique involves an incision in the labial mucosa followed by supraperiosteal dissection, in which the flap is repositioned inferiorly and sutured at the desired vestibular depth. Consequently, the denuded area is located primarily on the labial surface and heals by secondary intention. The main limitation of this technique is scar contraction, which may lead to a loss of the achieved vestibular depth (Kazanjian, 1935).

A more recent study demonstrated that modifications of the original technique were associated with less postoperative pain and more favorable healing (Mohanty *et al.*, 2025). These findings, together with the clinical characteristics of the case, supported our choice of the modified Kazanjian technique. In the present case, the periosteum was sutured to the labial mucosa, while the alveolar mucosa was repositioned to cover the underlying bone and stabilized at the level of the muscle attachments. This configuration may help reduce scar contraction, based on the principle that contraction of a denuded surface is reduced when it is covered by epithelium (Kumar *et al.*, 2016). Thus, maintaining the alveolar mucosa over the bone reduces the extent of the area left exposed to heal by secondary intention, while stabilizing the periosteum and mucosa at different positions may favor the maintenance of vestibular depth. In addition to the potential for reduced contraction associated with the selected technique, the flap was designed to measure approximately 1.5 times the desired final vestibular depth to compensate for the anticipated scar contraction.

Kumar *et al.* (2016) evaluated the effectiveness of the modified Kazanjian technique for increasing mandibular vestibular depth in a clinical study involving 10 patients. They observed satisfactory healing and a mean gain in vestibular depth of 11 mm, as well as high patient satisfaction with the new prosthesis. In the present case, although standardized measurements of vestibular depth were not obtained before and after surgery, a clinically evident increase in

This article is published in open access under the Creative Commons Attribution 4.0 International (CC BY 4.0) license, which permits unrestricted use, distribution, and reproduction in any medium, provided that the original author and source are credited.

vestibular depth was observed and remained apparent at the 30-day follow-up. Additionally, during the try-in stages of the new complete denture, the patient reported improved prosthetic stability and retention. These findings are consistent with those reported by Kumar *et al.* (2016), although the absence of objective measurements and long-term follow-up limits direct comparison between the cases.

Thus, the technique employed in the present case represents a vestibuloplasty approach based on the repositioning and stabilization of soft tissues, with specific features that distinguish it from the originally described Kazanjian technique. Despite its potential benefits in terms of bone coverage and vestibular deepening, the predictability of the outcome should be interpreted in light of the possibility of scar contraction and relapse. Therefore, appropriate surgical planning that accounts for these factors, together with long-term follow-up, is essential.

4. FINAL CONSIDERATIONS

The modified Kazanjian technique demonstrated favorable clinical outcomes in increasing vestibular depth, contributing to improved prosthetic retention and stability. Furthermore, it represents a surgical alternative that may reduce the need for more extensive procedures, such as bone or soft tissue grafting. However, the absence of objective measurements of vestibular depth and the limited follow-up period of 30 days constitute limitations of this case report, precluding a quantitative assessment of the gain achieved and the long-term stability of the results. Studies with longer follow-up periods and standardized clinical assessments are needed to better establish the predictability of this surgical approach.

REFERENCES

Clark HB Jr. Deepening of labial sulcus by mucosal flap advancement. J Oral Surg. 1953;11(2):165-8.

Dąbrowski W, Kaluźniak-Szymanowska A, Jagiełło K, Wierucki Ł, Górska R, Kujawska-Danecka H, *et al.* Tooth loss, denture use, and risk of malnutrition in older adults in Poland: evidence from the National PolSenior2 Study. Nutrients. 2026;18(6):1010. doi:10.3390/nu18061010.

Godwin JG. Submucous surgery for better denture service. J Am Dent Assoc. 1947;34(10):678-86. doi:10.14219/jada.archive.1947.0147.

House MM. Classification of osseous, muscular, and tissue conditions of edentulous mouths. In: Nichols IG. Prosthetic dentistry: an encyclopedia of full and partial denture prosthesis. St. Louis: CV Mosby; 1930. p. 90-1.

This article is published in open access under the Creative Commons Attribution 4.0 International (CC BY 4.0) license, which permits unrestricted use, distribution, and reproduction in any medium, provided that the original author and source are credited.

Kazanjian VH. Surgery as an aid to more efficient service with prosthetic dentures. J Am Dent Assoc. 1935;22(4):566-81.

Kumar JV, Chakravarthi PS, Sridhar M, Devi KNN, Kattimani VS, Lingamaneni KP. Anterior ridge extension using modified Kazanjian technique in mandible: a clinical study. J Clin Diagn Res. 2016;10(2). doi:10.7860/JCDR/2016/16606.7192.

Leite FRM, Tay JRH, Chow DY, Ng E, Nascimento GG, Peres MA. Tooth loss and edentulism are associated with poorer quality of life: a systematic review and meta-analyses. J Periodontal Res. 2026. doi:10.1111/jre.70121.

Magro-Filho O, de Carvalho AC. Topical effect of propolis in the repair of sulcoplasties by the modified Kazanjian technique: cytological and clinical evaluation. J Nihon Univ Sch Dent. 1994;36(2):102-11. doi:10.2334/josnusd1959.36.102.

Marzola C. Cirurgia pré-protética. 3rd ed. São Paulo: Pancast; 2002.

Mohanty D, Srivani P, Katti N, Baral D, Raj SC, Dash BR. Evaluation of gained vestibular depth, pain perception and healing response following three different methods of vestibular deepening surgical techniques: a comparative clinical trial. J Indian Soc Periodontol. 2025;29(3):284-90. doi:10.4103/jisp.jisp_425_23.

Patil R, Suragimath G, Varma S, Zope SA, Ashwinirani SR. Edlan-Mejchar procedure: enhancing complete denture retention. Cureus. 2025;17(2):e78346. doi:10.7759/cureus.78346.

Ponzoni D, Jardim ECG, de Carvalho PS. Vestibuloplasty by modified Kazanjian technique in treatment with dental implants. J Craniofac Surg. 2013;24(4):1373-5. doi:10.1097/SCS.0b013e3182860524.

Sanz-Sánchez I, Sanz-Martín I, Ortiz-Vigón A, Molina A, Sanz M. Complications in bone-grafting procedures: classification and management. Periodontol 2000. 2022;88(1):86-102. doi:10.1111/prd.12413.

Tortorelli AF. A technique for vestibular sulcus extension. J Prosthet Dent. 1968;20(1):14-20. doi:10.1016/0022-3913(68)90208-4.

Trauner R. Alveoloplasty with ridge extension on lingual side of the lower jaw to solve the problem of a lower dental prosthesis. Oral Surg Oral Med Oral Pathol. 1952;5(4):340-6. doi:10.1016/0030-4220(52)90288-0.

Wyrębek B, Górska R, Gawron K, Nędzi-Góra M, Górski B, Plakwicz P. Periodontal condition of mandibular incisors treated with modified Kazanjian vestibuloplasty compared to untreated sites: a prospective study. Adv Clin Exp Med. 2021;30(7):681-90. doi:10.17219/acem/133492.

This article is published in open access under the Creative Commons Attribution 4.0 International (CC BY 4.0) license, which permits unrestricted use, distribution, and reproduction in any medium, provided that the original author and source are credited.